

Laser Peripheral Iridotomy and Iridoplasty

RYAN KERN OD, FAAO



UNIVERSITY OF PIKEVILLE
KENTUCKY COLLEGE OF OPTOMETRY

Objectives

- Lesser common indications for LPI
- Narrow angle suspects
- PAC/PACG
- Case examples
- Contraindications
- Positioning
- Complications
- Videos

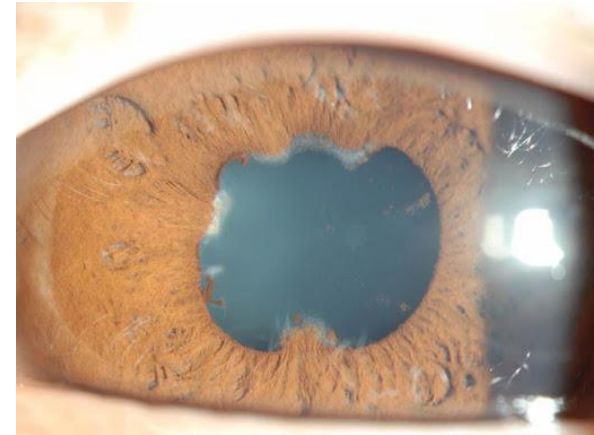
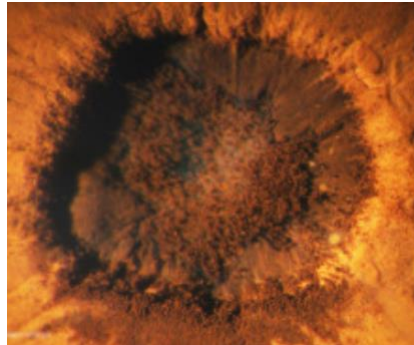
Glaucoma Classification

- “Secondary” angle closure classically refers to angle closure
 - Of a disease or dysgenesis process

- Authors argue that all glaucoma is secondary to an etiology
 - Therefore it may be more appropriate to refer to angle closure in relation to initial event or exact mechanism of obstruction
 - Which we tend to do anyways
 - But some authors don’t really like primary or secondary terminology due to non-specificity

Secondary Closure

- Posterior synechia and pupillary seclusion
 - LPI possibly indicated when secondary pupillary block occurs (not applied to the PS)
 - Various stages of angle closure
 - Or highly suspect for closure



Abo-Shasha, Rami. "Management of Pupillary Seclusion and Occlusion of an Iris Enclaved Intraocular Lens." *Define_me*, [https://www.canadianjournalofophthalmology.ca/article/S0008-4182\(20\)30631-1/fulltext](https://www.canadianjournalofophthalmology.ca/article/S0008-4182(20)30631-1/fulltext).

- LPI may have utility in acute episode
 - Lens extraction more likely desired procedure in this scenario with surgical synechiolysis

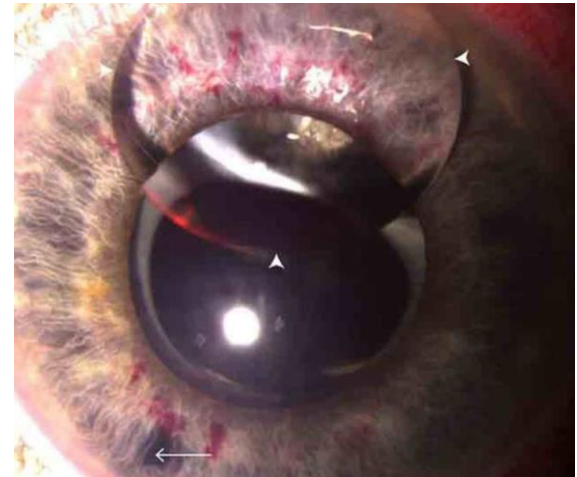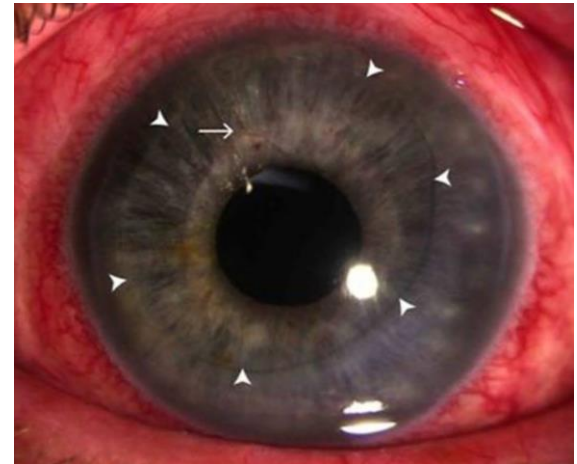Secondary Closure

- Silicone oil

- Can migrate anteriorly and occlude the pupil
- Causes a secondary pupillary block

- More likely if patient is s/p posterior capsulotomy
- More likely if patient is aphakic

- Inferior LPI (must be inferior to lower margin of oil)
- Allows vertical migration of oil
- And promotes regression at pupillary margin

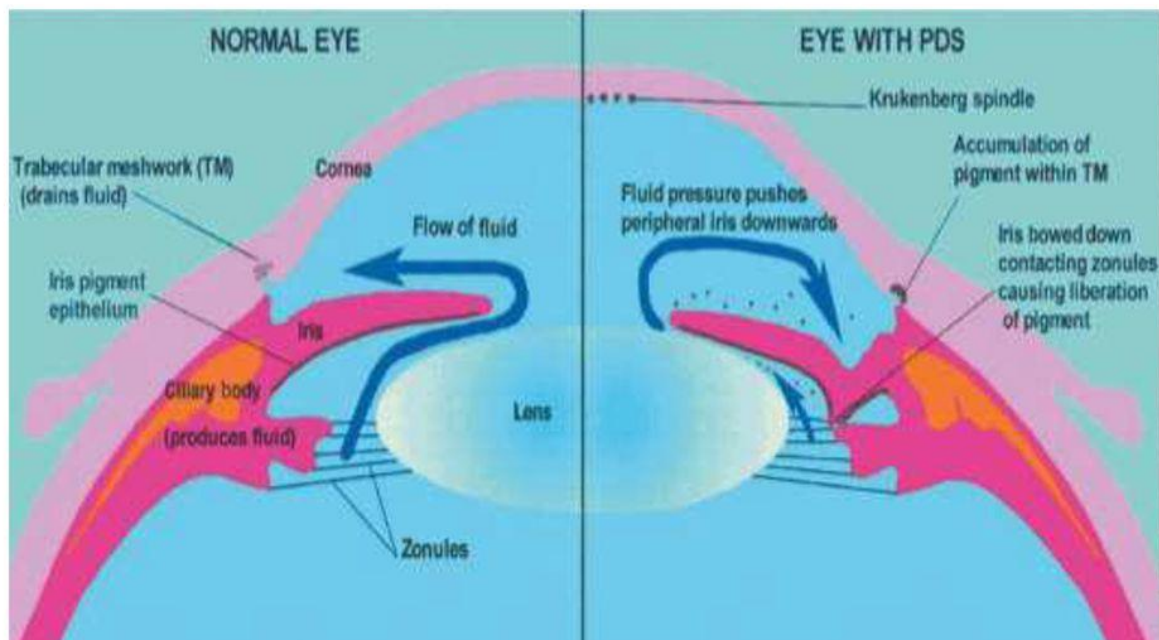


Yusuf, Imran H, et al. "Silicone Oil Pupil Block Glaucoma in a Pseudophakic Eye." *BMJ Case Reports*, BMJ Publishing Group, 23 Sept. 2014, <https://www.ncbi.nlm.nih.gov/pmc/articles/PMC4173143/>.

Secondary Closure

- Pigmentary dispersion and pigmentary glaucoma

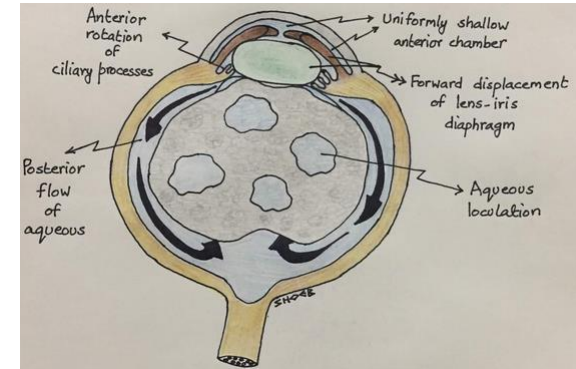
REVERSE PUPILLARY BLOCK IN PIGMENTARY GLAUCOMA



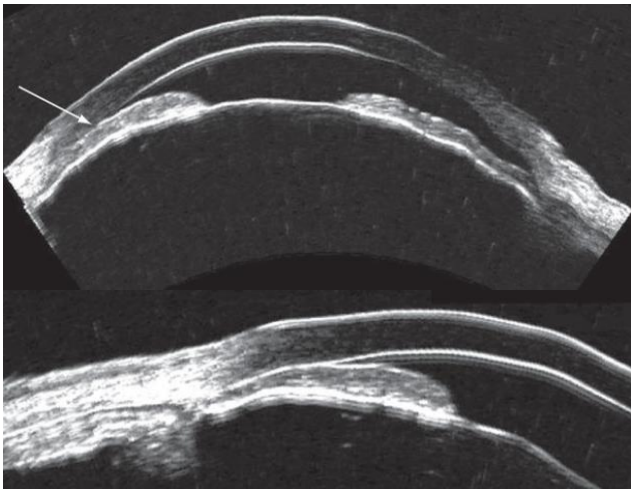
Themes, UFO. "17." *Ento Key*, 2 Sept. 2016, <https://entokey.com/17-2/>.

Secondary Closure

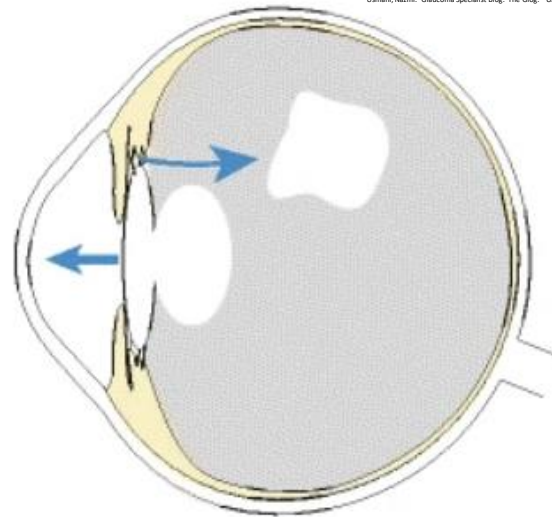
- Aqueous misdirection (malignant glaucoma)
 - Multiple theories of mechanism
 - Does not respond to LPI
 - But LPI is helpful in diagnosis
 - LPI with zonulo-hyaloidotomy is a treatment option



Usmani, Nazim. "Glaucoma Specialist Blog: 'The Glog'." GLAUCOMA SPECIALIST BLOG: "THE GLOG", 16 June 2019. <http://ourpc.blogspot.com/2019/06/malignant-glaucoma-guest-author-nazim-hos>




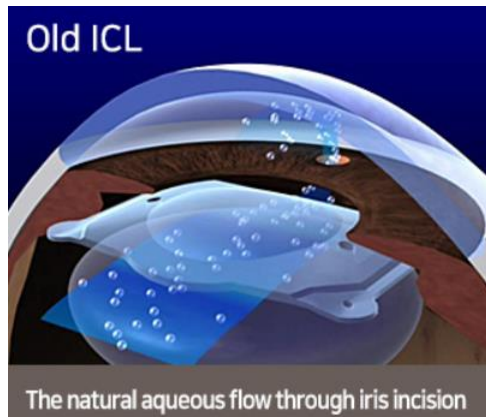
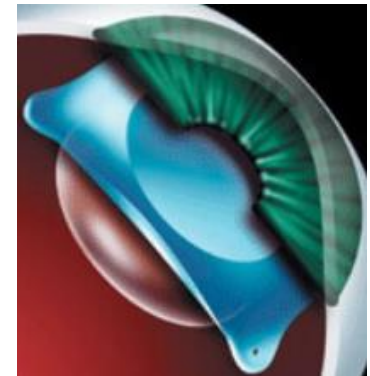
Urso, Roxana. "Ultrasound Biomicroscopy Images of Malignant Glaucoma." https://www.researchgate.net/figure/Ultrasound-biomicroscopy-images-of-malignant-glaucoma-A-Anterior-segment-in-horizontal_fig4_42372682.



Debrouwere, Veroniek, et al. "Outcomes of Different Management Options for Malignant Glaucoma: A Retrospective Study - Graefes Archive for Clinical and Experimental Ophthalmology." SpringerLink, Springer-Verlag, 20 Aug. 2011. <https://link.springer.com/article/10.1007/s00417-011-1763-0/figures/4>.

Secondary Closure

- Visian ICL (implantable collamer lens) (maybe no more?)
 - Previous models required an LPI prior to or an iridectomy during the procedure to reduce secondary pupillary block
 - The EVO Visian ICL has a small hole in the optic
 - Prevents secondary pupillary block
 - Has been studied since 2005 and used globally since 2011
 - The FDA just approved the EVO model in the US as of March 2022



*Eyereum Menu™ EYEREUM, <https://eyereum.com/enj/center/icl>

Narrow Angle Suspects

- Pupillary block, plateau iris configuration or both?
- We know classic pupillary block as the number 1 cause of primary acute angle closure
- We know plateau iris configuration as an abnormal anatomical anterior displaced ciliary body and anterior insertion of the iris root
- We know these 2 conditions can coexist to variable degrees

Occludable?

- 180 degrees or 2 quadrants of iridotrabecular contact
 - Constitutes a suspect for angle closure determined by gonioscopy
- Indentation gonioscopy with Sussman or Posner 4 mirror lenses
- Symptoms? Signs?
- Risk factors?
- OCT/UBM?

Glaucoma Classification

- “Primary” angle closure glaucoma
 - Classically refers to closure of the anterior chamber angle by appositional iridotrabecular contact
 - Inciting an IOP spike and optic nerve damage within the setting of “normal” anatomy
 - Without separate associated disease process

Pupillary Block

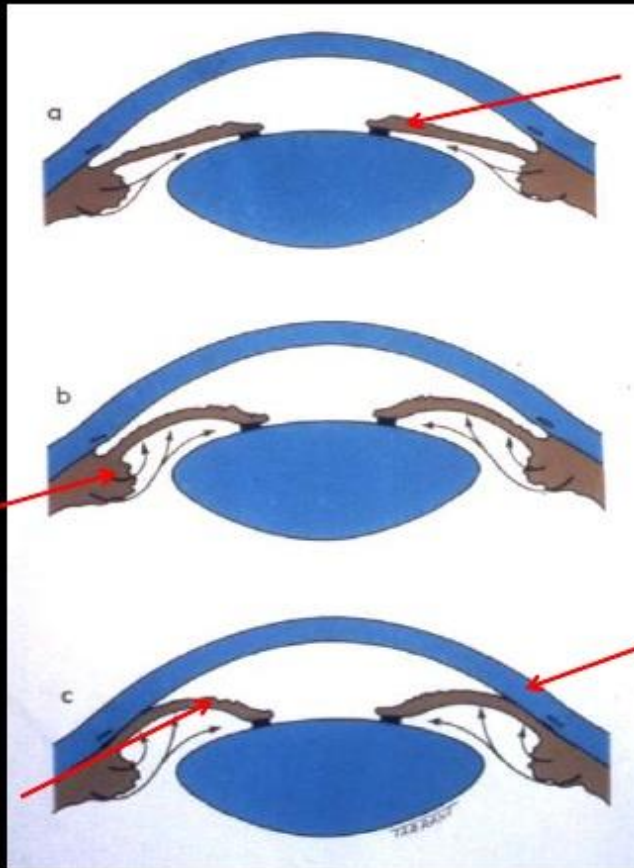
- Most common form of angle closure
- Initiating event
 - Result of increased resistance to flow of aqueous
 - Between pupillary portion of the iris and the anterior lens surface
- Associated with mid-dilation of the pupil
 - Where it may have great potential for contact during normal function
- Functional block causes increased fluid pressure in the posterior chamber
 - Resulting in forward shift of the iris
- Anterior movement of peripheral iris
 - Causes a bowing/contact of the iris anterior to trabecular meshwork
 - Termed iris bombe

Pupillary Block

- Related to:
 - A thicker/more anatomically placed lens
 - A smaller diameter, shorter posterior curvature cornea
 - A shorter axial length

- Mid-dilated pupil, hypothesized to be anywhere from 3.5-6mm in diameter, may potentiate highest risk of pupillary block

PHYSIOLOGICAL PUPILLARY BLOCK

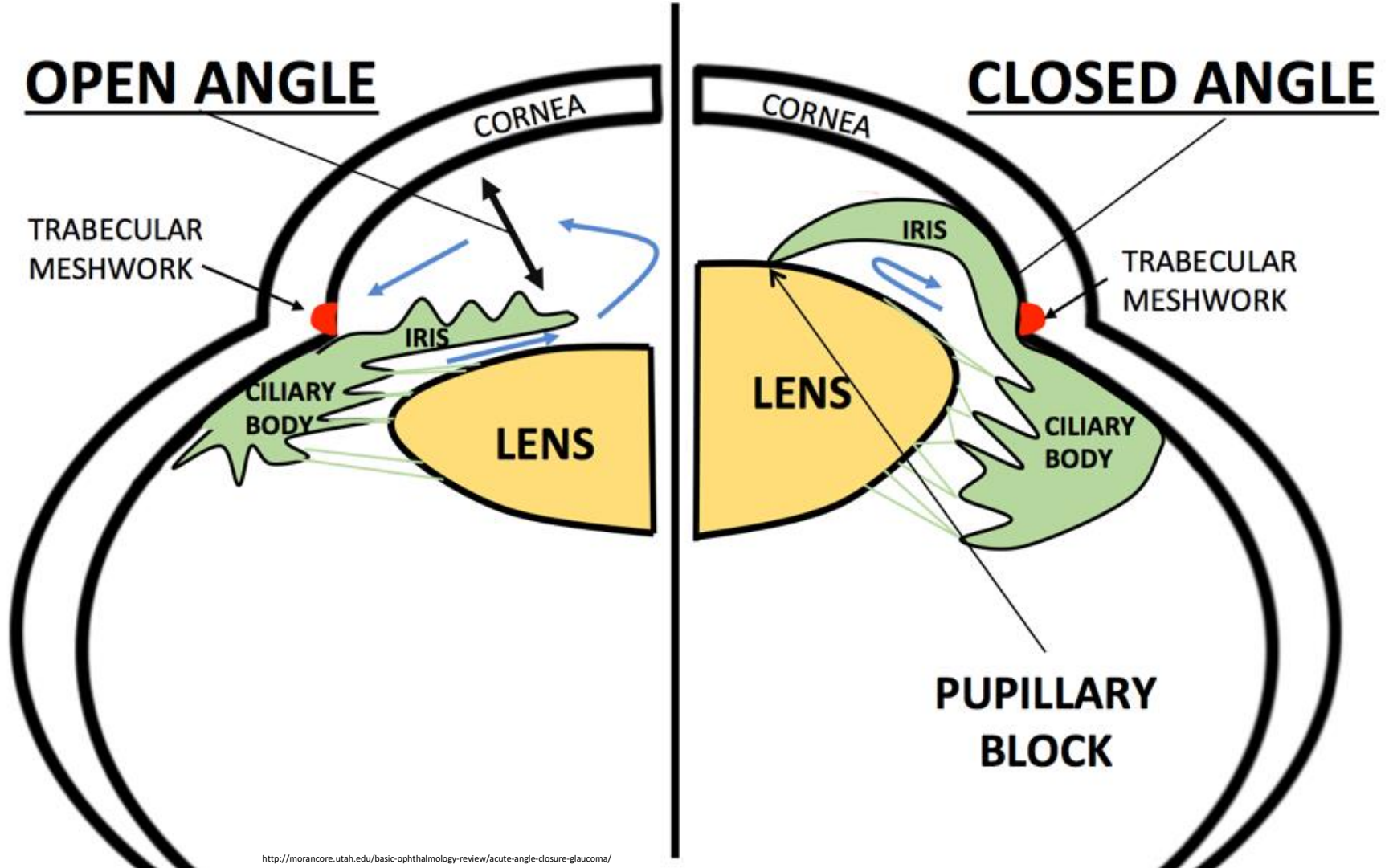


1. Iris has large arc of contact with anterior surface of lens

2. Resistance to aqueous flow from posterior to anterior chamber (*relative pupil block*)

3. Pupil dilates, peripheral iris becomes more flaccid and pushed anteriorly



4. Iris lies against trabecular meshwork → impede aqueous humor drainage → ↑ IOP



Pushing Mechanism of Closure W/o Pupillary Block – Plateau Iris

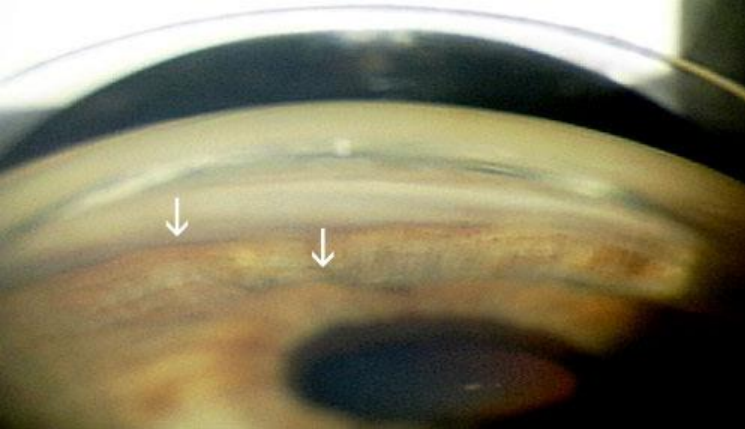
- Plateau iris configuration

- Based on gonioscopic findings (pre-surgically) with a narrow/closed angle and a flat iris that may have minimal iris bombe
- There may be a relative pupillary block component
 - Which is relieved after iridotomy

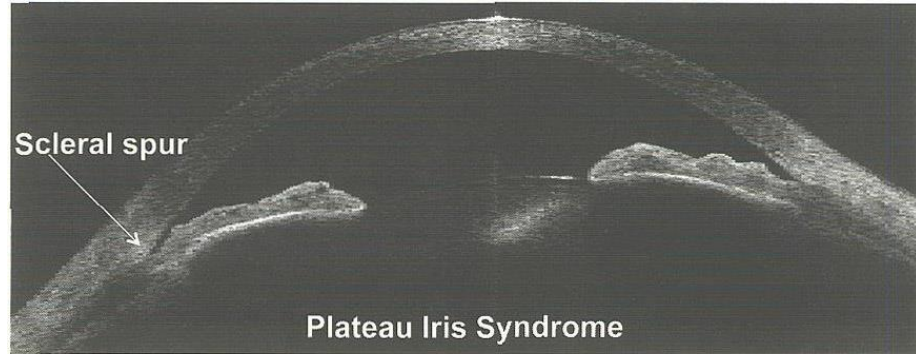


- Plateau iris syndrome

- Based (post-surgically) on the persistent presence of a closed/narrowed angle that did not allow deepening of the anterior chamber and opening of the angle
- Anterior displacement of the ciliary body and anterior insertion of iris root

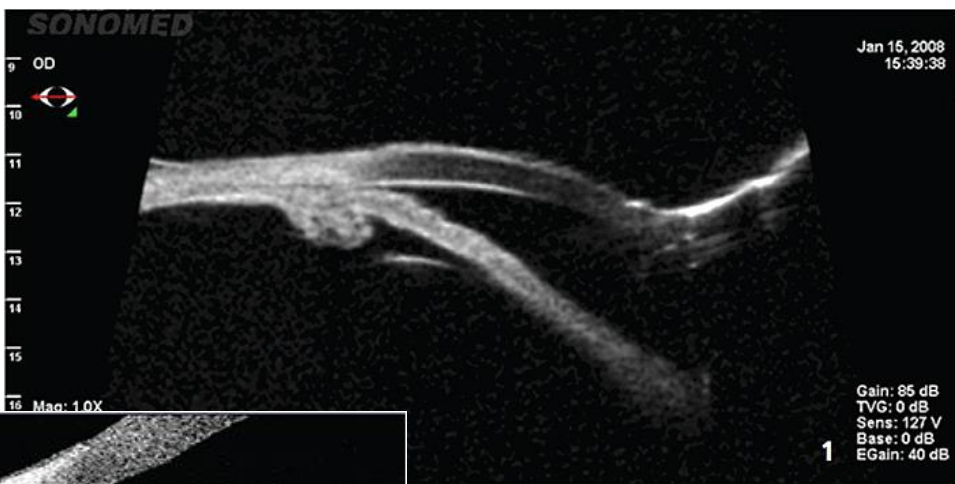

<https://webeye.ophth.uiowa.edu/eyeforum/cases/143-plateau-iris.htm>

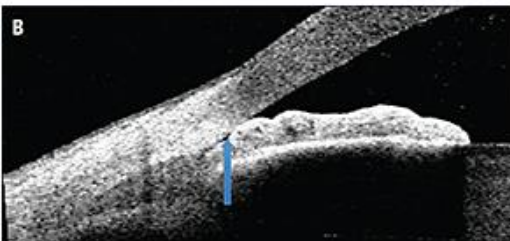
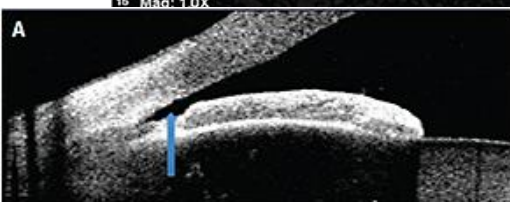


4. This patient presented with plateau iris syndrome. Notice how the peripheral iris is mechanically positioned against the trabecular meshwork.

<https://go.gale.com/ps/anonymous?id=GALE%7CA210847900&sid=googleScholar&v=2.1&it=r&linkaccess=fulltext&issn=1930160X&p=AONE&sw=w>

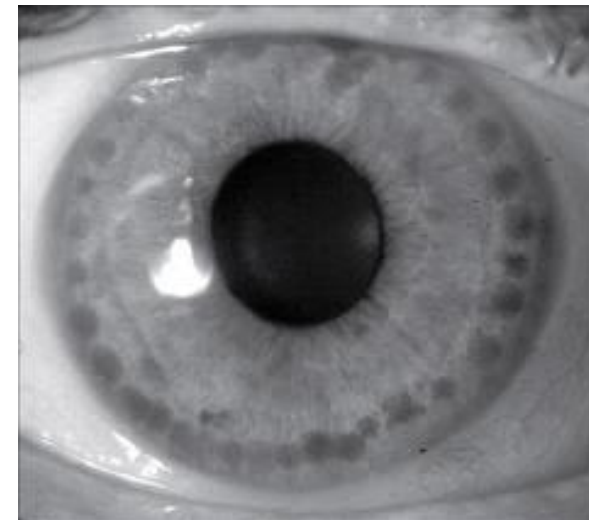


IMAGES COURTESY BRIAN FRANCIS, MD, MS



<https://www.ophthalmologymanagement.com/issues/2014/may-2014/anterior-segment-oct-in-glaucoma-management>

<http://www.vision-and-eye-health.com/glaucoma-laser.html>



Iridoplasty

Peripheral burns applied to the iris causing contraction effectively pulling the iris out of the angle

Applied when LPI does not change presence of occluded or potentially occluded angle in the setting of plateau iris syndrome

Conduct an exam with basic entrance testing, may consider anterior segment OCT/UBM and address macular/retinal status

Informed consent, pre/post operative brimonidine, pre-operative pilocarpine, post operative prednisolone acetate 1gtt QID 1 week

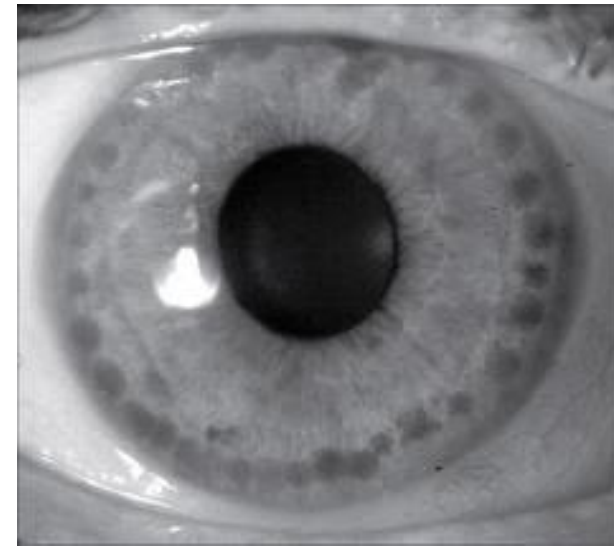
200-300mW

500um spot size

0.5-0.7sec

Circumferential pattern with minimal spacing between burns

Does not burn complete holes in the iris, but exposes darkly pigmented epithelial layers



<http://www.vision-and-eye-health.com/glaucoma-laser.html>

Occludable?

- 180 degrees or 2 quadrants of iridotrabecular contact
 - Constitutes a suspect for angle closure determined by gonioscopy
- Indentation gonioscopy with Sussman or Posner 4 mirror lenses
 - A pupillary block component will reveal deeper angle structures
- Symptoms? Signs?
- Risk factors?
- OCT/UBM?
- LPI on an asymptomatic patient???

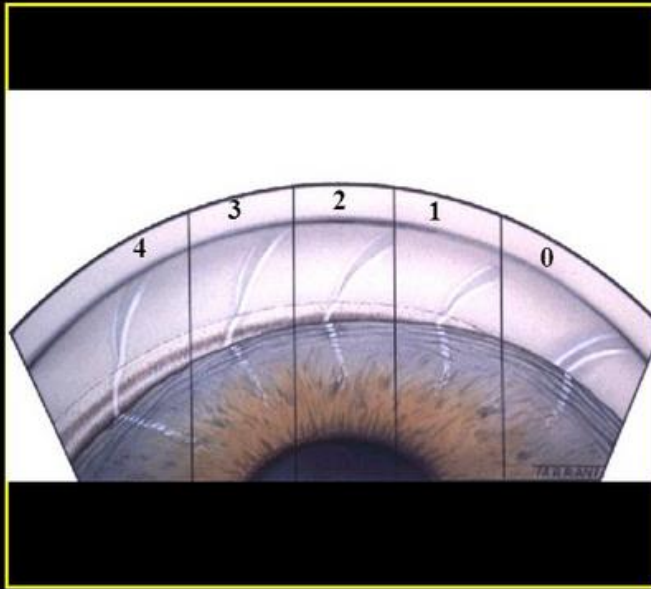
Gonioscopy vs. OCT

Gonioscopy	OCT
Subjective	Objective
Rapid 360-degree assessment	Time-consuming; not practical for scanning 360 degrees with current FDA-approved devices
Requires contact; some patients cannot tolerate contact procedures	Non-contact; comfortable for patient
360-degree assessment	Cross-sectional view; not practical for scanning 360 degrees
Requires illumination	Can be performed in the dark
Can detect other causes of elevated IOP such as pigment dispersion or angle recession	Cannot assess angle features other than angle width
Indentation possible, revealing PAS, plateau configuration	Indentation not possible
Limited information about the anterior chamber	Snapshot of entire anterior chamber in one scan
Scleral spur can be misidentified if trabecular meshwork is pale or Schwalbe's line is pigmented	Scleral spur can't be identified in up to 30 percent of angle images
Angle width measurement is subjective	Angle width measurement is objective, but variability can be high

Santa Rathakrishnan, MD. "Diagnosing Angle Closure: Gonioscopy vs. Oct." Review of Ophthalmology, 5 Apr. 2015. <https://www.reviewofophthalmology.com/article/diagnosing-angle-closure-gonioscopy-vs-oct>.

Gonioscopy

Shaffer grading of angle width

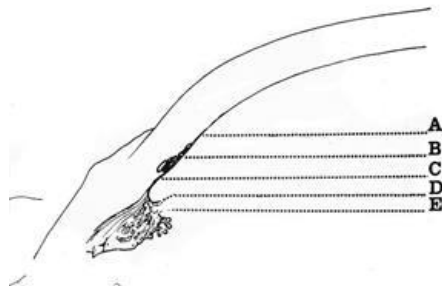


The diagram illustrates the Shaffer grading system for angle width, showing five zones from 0 to 4. Zone 0 is the narrowest, showing only the Schwalbe line and the top of the trabeculum. Zone 1 shows the Schwalbe line and the top of the trabeculum. Zone 2 shows the trabeculum. Zone 3 shows the scleral spur. Zone 4 is the widest, showing the ciliary body.

- Grade 4 (35-45 °)**
 - Ciliary body easily visible
- Grade 3 (25-35 °)**
 - At least scleral spur visible
- Grade 2 (20 °)**
 - Only trabeculum visible
 - Angle closure possible but unlikely
- Grade 1 (10 °)**
 - Only Schwalbe line and perhaps top of trabeculum visible
 - High risk of angle closure
- Grade 0 (0 °)**
 - Iridocorneal contact present
 - Apex of corneal wedge not visible
 - Use indentation gonioscopy

"Angle Closure Can Be Missed Using the Van Herick Method." Dr Vincent Lee, <http://www.drvincentlee.com.au/news/angle-closure-can-be-missed-by-van-herick-technique>.

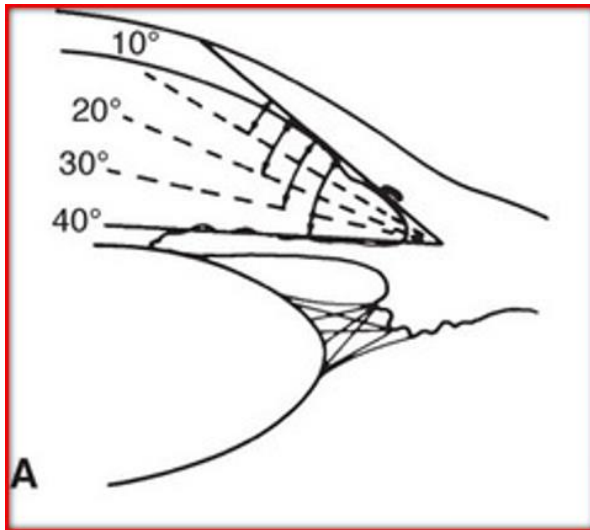
Gonioscopy



S. Myers Gonioscopy Lecture

- Grades 3 major features of the angle's anatomy
 - **Iris insertion**
 - A: At or anterior; anterior to SL
 - B: Between SL and SS (TM)
 - C: Scleral spur (SS)
 - D: Deep; deep into the CB
 - E: Extremely deep; deeper into the CB
 - Width of angle
 - Configuration of iris

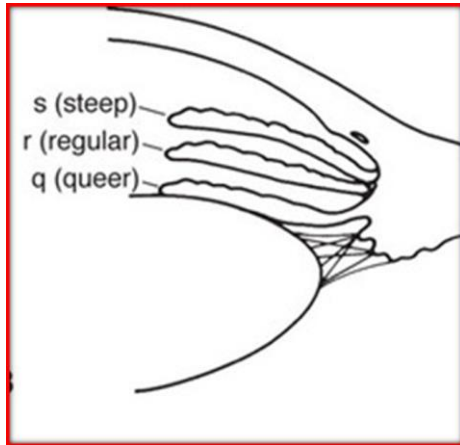
Gonioscopy



S. Myers Gonioscopy Lecture

- Grades 3 major features of the angle's anatomy
 - Iris insertion
 - **Width of angle**
 - estimated angle between a line tangential to the trabecular meshwork and a line tangential to the surface of the iris about one-third of the way from the periphery
 - expressed in degrees
 - 0-50 degrees
 - 20-45 degrees wide open
 - Configuration of iris

Gonioscopy

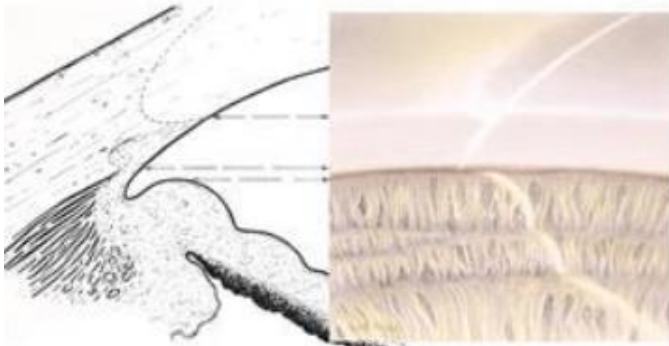


S. Myers Gonioscopy Lecture

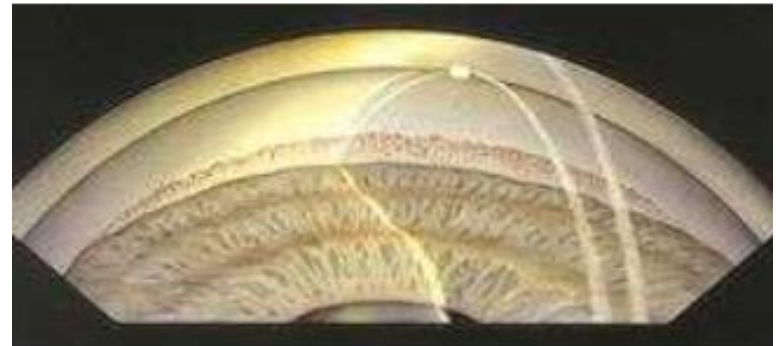- Grades 3 major features of the angle's anatomy
 - Iris insertion
 - Width of angle
 - **Configuration of iris (old)**
 - r: regular or flat
 - s: steep or bombe
 - q: queer or concave
 - **Configuration of iris (new)**
 - f: flat
 - c: concave
 - b: bowed
 - p: plateau

Gonioscopy

- Gonioscopy has many challenges
 - 3 of the most common and diagnostically problematic challenges are as follows:
- Left, you can see CB, but other than that there isn't any pigment
 - Imagine if CB wasn't visible in this view
 - How would you know if you are looking at SS or SL???
- Right: In a narrow angle covering the TM, if SL is pigmented with Sampaolesi's line, you may mistake this for PTM and think this quadrant is open
- 3rd Challenge: Your touch isn't light enough with the flangeless gonioscopy lens, and you are artificially indenting
 - Will make angle look more open it really is if there is pupillary block component

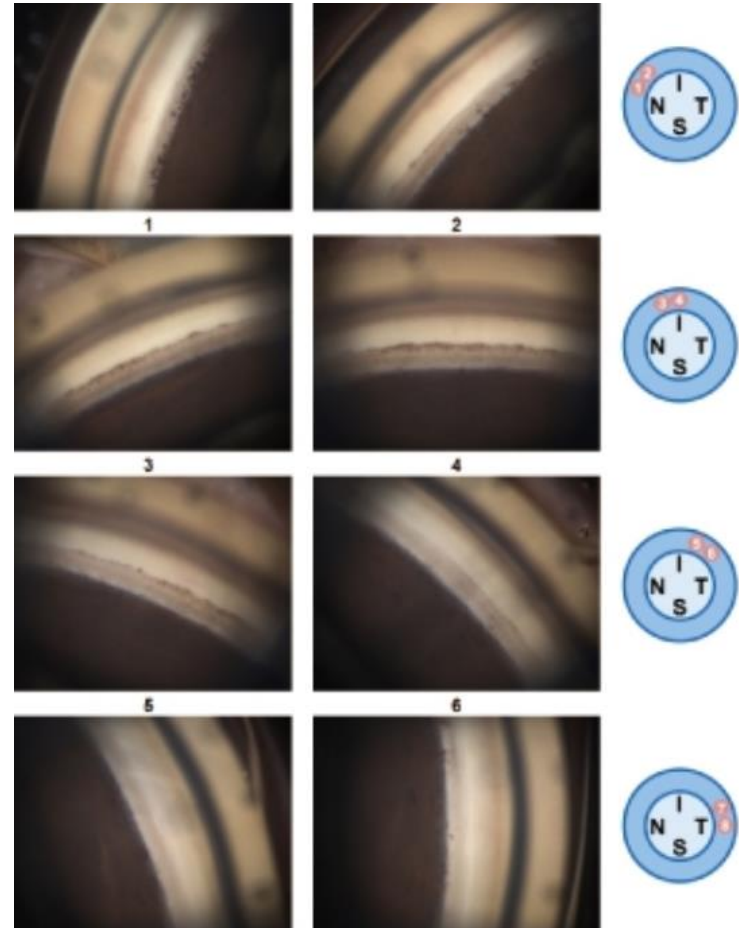
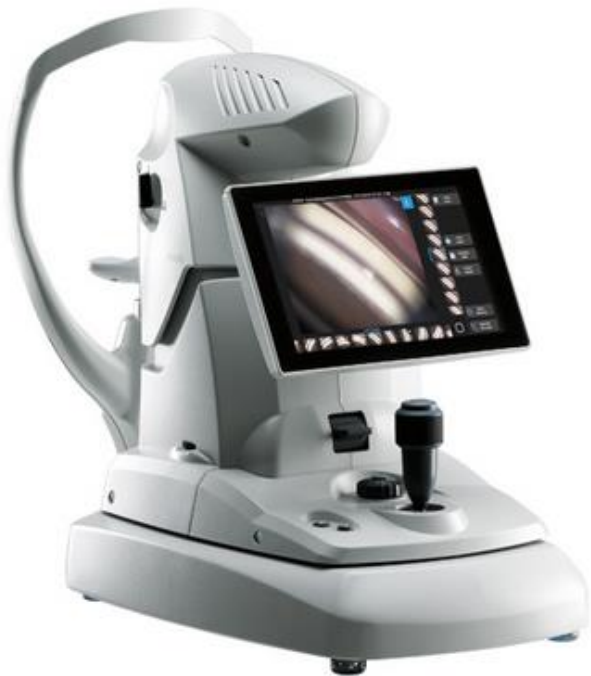

MD, Wallace L M Alward, and Reid A Langmuir MD. "The Normal Angle." American Academy of Ophthalmology, 24 June 2021. <https://www.aao.org/boosee-review/the-normal-angle>



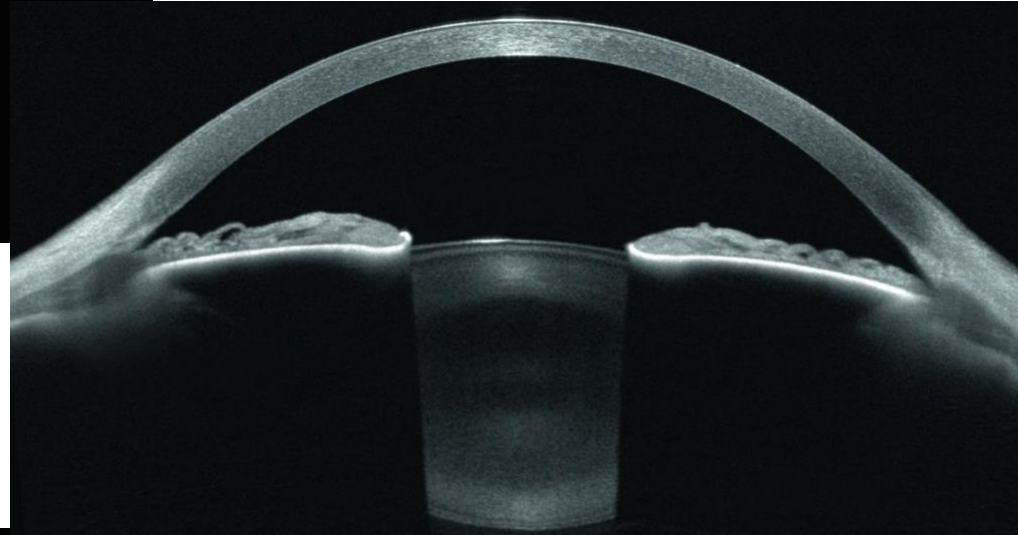
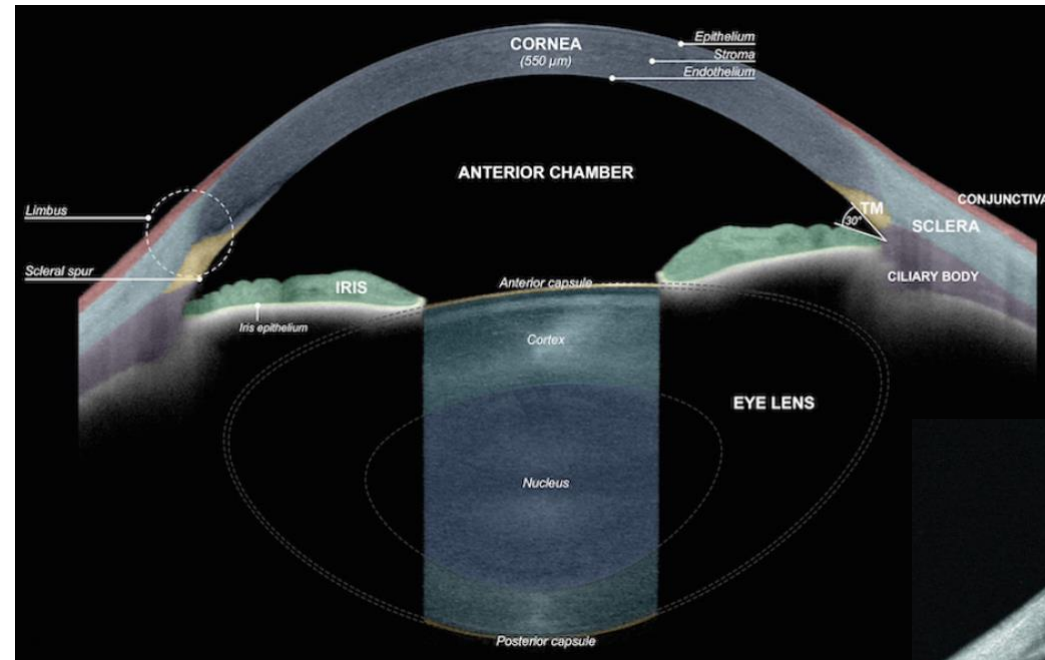
MD, Wallace L M Alward, and Reid A Langmuir MD. "Abnormalities Associated with a Closed Angle." American Academy of Ophthalmology, 24 June 2021. <https://www.aao.org/boosee-review/abnormalities-associated-with-closed-angle>

Gonioscopy (Gonioscope GS-1)

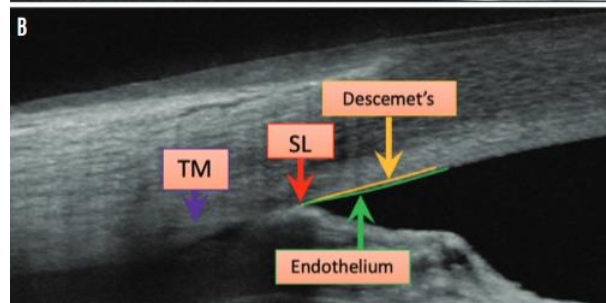
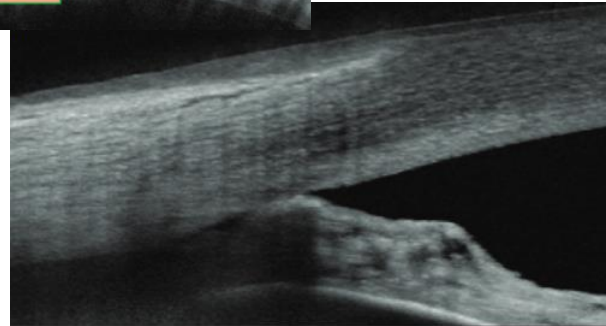
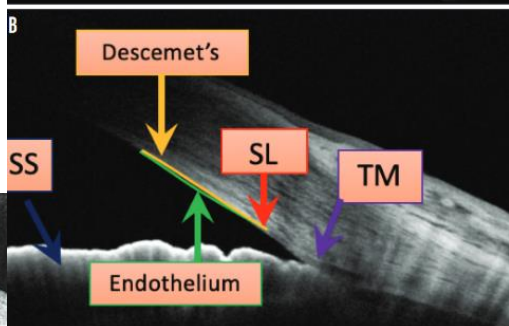
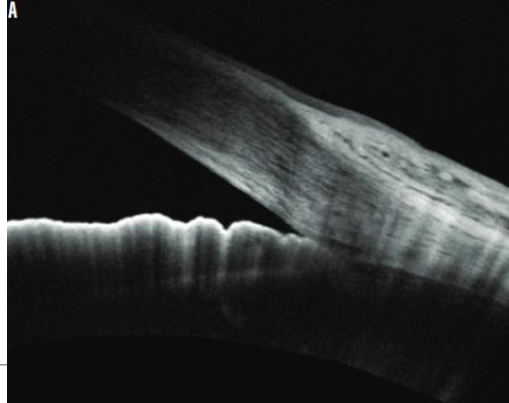
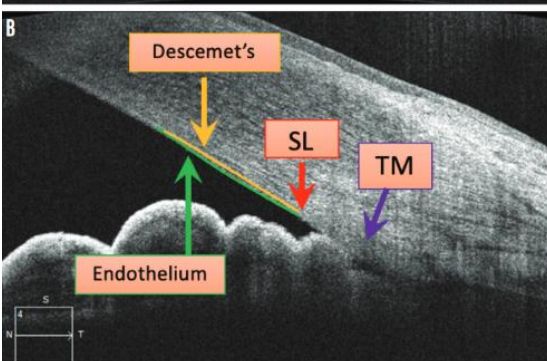
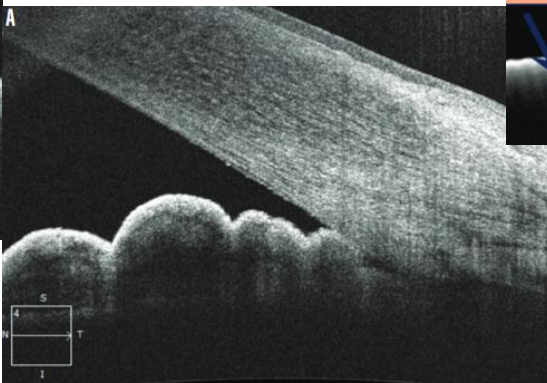

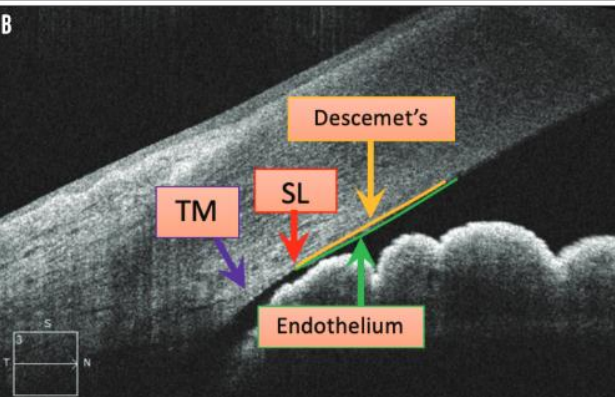
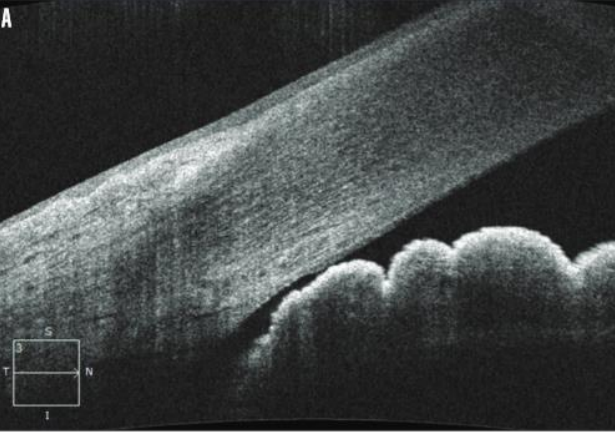


*Gonioscope GS-1: Retina & Glaucoma; Nidek Co., Ltd. Eye & Health Care; NIDEK CO., LTD. https://www.nidek-ent.com/product/ophthalmoptom/diagnostic/ga_retina/gs-1.html.

OCT



*Academy of Ocular Coherence Academy, <https://academy.heldref.com/ocw.php?file=3152he-local-en-US%20country-US%20he-stereo>



Longitudinal Changes of Angle Configuration in Primary Angle-Closure Suspects:

The Zhongshan Angle-Closure Prevention Trial

Yuzhen Jiang, MSc, MD^{1,2}, Dolly S. Chang, MD, PhD^{2,3}, Haogang Zhu, MSc, PhD¹, Anthony P. Khawaja, MPhil, FRCOphth⁴, Tin Aung, PhD, FRCS(Ed)⁵, Shengsong Huang, MSc, MD², Qianyun Chen, BA, MA², Beatriz Munoz, MSc³, Carlota M. Grossi, BSc, PhD¹, Mingguang He, MD, PhD^{#1,2}, David S. Friedman, MD, PhD^{#2,3,6}, and Paul J. Foster, PhD, FRCS(Ed)^{#1,2,7}

¹UCL Institute of Ophthalmology, University College London and Moorfields Eye Hospital, London, United Kingdom. ²State Key Laboratory of Ophthalmology, Zhongshan Ophthalmic Center, Sun Yat-sen University, Guangzhou, China. ³Wilmer Eye Institute, Dana Center for Preventive Ophthalmology, Johns Hopkins University, Baltimore, Maryland. ⁴Department of Public Health and Primary Care, Institute of Public Health, University of Cambridge School of Clinical Medicine, Cambridge, United Kingdom. ⁵Singapore Eye Research Institute, Singapore National Eye Center, Singapore and National University of Singapore, Singapore. ⁶Department of International Health, Johns Hopkins Bloomberg School of Public Health, Baltimore, Maryland. ⁷NIHR Biomedical Research Centre at Moorfields Eye Hospital, London, United Kingdom.

[#] These authors contributed equally to this work.

Abstract

Objective—To determine longitudinal changes in angle configuration in the eyes of primary angle-closure suspects (PACS) treated by laser peripheral iridotomy (LPI) and in untreated fellow eyes.

Design—Longitudinal cohort study.

Participants—Primary angle-closure suspects aged 50 to 70 years were enrolled in a randomized, controlled clinical trial.

Methods—Each participant was treated by LPI in 1 randomly selected eye, with the fellow eye serving as a control. Angle width was assessed in a masked fashion using gonioscopy and anterior segment optical coherence tomography (AS-OCT) before and at 2 weeks, 6 months, and 18 months after LPI.

Main Outcome Measures—Angle width in degrees was calculated from Shaffer grades assessed under static gonioscopy. Angle configuration was also evaluated using angle opening

distance (AOD250, AOD500, AOD750), trabecular-iris space area (TISA500, TISA750), and angle recess area (ARA) measured in AS-OCT images.

Results—No significant difference was found in baseline measures of angle configuration between treated and untreated eyes. At 2 weeks after LPI, the drainage angle on gonioscopy widened from a mean of 13.5° at baseline to a mean of 25.7° in treated eyes, which was also confirmed by significant increases in all AS-OCT angle width measures ($P < 0.001$ for all variables). Between 2 weeks and 18 months after LPI, a significant decrease in angle width was observed over time in treated eyes ($P < 0.001$ for all variables), although the change over the first 5.5 months was not statistically significant for angle width measured under gonioscopy ($P = 0.18$), AOD250 ($P = 0.167$) and ARA ($P = 0.83$). In untreated eyes, angle width consistently decreased across all follow-up visits after LPI, with a more rapid longitudinal decrease compared with treated eyes (P values for all variables ≤ 0.003). The annual rate of change in angle width was equivalent to 1.2°/year (95% confidence interval [CI], 0.8–1.6) in treated eyes and 1.6°/year (95% CI, 1.3–2.0) in untreated eyes ($P < 0.001$).

Conclusions—Angle width of treated eyes increased markedly after LPI, remained stable for 6 months, and then decreased significantly by 18 months after LPI. Untreated eyes experienced a more consistent and rapid decrease in angle width over the same time period.

Risk of Closure in Asymptomatic Patients in General?

The Risk of Primary Angle Closure Suspects Developing Acute Primary Angle Closure*					
Region	Enrollment criteria	Age	Mean follow-up period	Number of cases	Number that developed APAC
Guangzhou, China ⁶	(1) anterior chamber depth ≤ 2 mm; (2) peripheral anterior chamber depth $\leq 1/4$ CT; or (3) iris light band ratio $\leq 1/4$	≥ 40 years	4.8 years (one to six years)	485	6 (1.2 percent)
Chicago, USA ⁷	(1) anterior chamber depth < 2 mm; (2) anterior chamber angle that the initial examining ophthalmologist believed was narrow enough to be capable of closure	Mean age: 62.1 years (range: 36.9 to 84.3 years)	2.7 years (one to six years)	129	8 (6.2 percent)
Vellore, India ³	(1) Nonvisibility of the filtering trabecular meshwork for 180 degrees or more; (2) IOP less than 22 mmHg; and (3) no peripheral anterior synechiae in the angle.	Mean age: 54.8 years (range: 36 to 65 years)	Five years, or the time to having met the endpoints	48	0

*Based on Zhang, Liu, Wang et al, 2017¹ <https://www.reviewofophthalmology.com/article/the-asymptomatic-pac-suspect-lpi-or-no-lpi>

- What about with dilation?
 - $\sim 0-1.3\%$

The 4 Forms of Angle Closure

- Acute angle closure glaucoma
- Sub-acute angle closure glaucoma
- Chronic angle closure glaucoma
- Combined mechanism glaucoma

RESEARCH ARTICLE

Comparing Laser Peripheral Iridotomy to Cataract Extraction in Narrow Angle Eyes Using Anterior Segment Optical Coherence Tomography

Ephrem Melese¹, Jeffrey R. Peterson^{1,2}, Robert M. Feldman^{1,2}, Laura A. Baker¹, Nicholas P. Bell^{1,2}, Alice Z. Chuang², Lauren S. Blieden^{1,2*}

Conclusions

CE results in greater anatomic changes in the ACA than LPI in PAC spectrum eyes. ASOCT may be used to follow anatomic changes in the angle after intervention.

Lens Position Parameters as Predictors of Intraocular Pressure Reduction After Cataract Surgery in Glaucomatous Versus Nonglaucomatous Eyes

Paul Coh,¹ Sasan Moghimi,^{1,2} Rebecca I. Chen,^{1,3} Chi-Hsin Hsu,^{1,4} Marissé Masís Solano,^{1,5} Travis Porco,⁶ and Shan C. Lin¹

CONCLUSIONS. Intraocular pressure reduction after phacoemulsification cataract surgery in nonglaucomatous eyes is significantly greater in more anteriorly positioned lenses. Though it did not reach statistical significance in patients with glaucoma, the association of LP with IOP reduction is in the same direction as in nonglaucomatous patients where smaller LP appears to predict greater IOP reduction. Lens position is a simple, easily calculable, accurate, and widely available parameter, which clinicians can potentially utilize in managing glaucoma.

The role of lens extraction in glaucoma management

Jolly L. Tsui^{1,2}, Noel C. Chan^{1,2}, Clement C. Tham^{1,2,3}

Points to note

- (I) Lens extraction can reduce IOP and IOP-lowering medication requirements in PAC disease. However, associated risks should be considered and carefully communicated to patients;
- (II) In PAC diseases with no optically significant cataract, clear lens extraction has been advocated for its superior ability in reducing IOP and IOP-lowering medication requirements compared to the standard treatment with LPI and medical therapy, and for its additional benefit of improving visual function by correcting refractive errors;
- (III) Combined phacotrabeculectomy can lead to further reduction in IOP and IOP-lowering medication requirements in PAC diseases but is related to increased risk of complications;
- (IV) The effect of lens extraction in POAG and OHT is less well studied but literature has suggested its effectiveness in reducing IOP and IOP-lowering medication requirements even though the results are not as pronounced compared to PAC disease;
- (V) Combined phacotrabeculectomy in POAG and OHT can result in further IOP and IOP-lowering medication requirement reduction compared to lens extraction alone but is associated with more complications;
- (VI) Earlier lens extraction has the benefit of preventing cataract formation in cases where further glaucoma surgeries are required and filtration failure in those previously trabeculectomized;
- (VII) Lens extraction has been shown to be able to reduce the postoperative IOP and diurnal IOP variations in NTG, which has been proposed to be an important pathogenic mechanism in this specific glaucoma subtype.

Effectiveness of early lens extraction for the treatment of primary angle-closure glaucoma (EAGLE): a randomised controlled trial

Augusto Azuara-Blanco, Jennifer Burr, Craig Ramsay, David Cooper, Paul J Foster, David S Friedman, Graham Scotland, Mehdi Javanbakht, Claire Cochrane, John Norrie, for the EAGLE study group

Summary

Background Primary angle-closure glaucoma is a leading cause of irreversible blindness worldwide. In early-stage disease, intraocular pressure is raised without visual loss. Because the crystalline lens has a major mechanistic role, lens extraction might be a useful initial treatment.

Methods From Jan 8, 2009, to Dec 28, 2011, we enrolled patients from 30 hospital eye services in five countries. Randomisation was done by a web-based application. Patients were assigned to undergo clear-lens extraction or receive standard care with laser peripheral iridotomy and topical medical treatment. Eligible patients were aged 50 years or older, did not have cataracts, and had newly diagnosed primary angle closure with intraocular pressure 30 mm Hg or greater or primary angle-closure glaucoma. The co-primary endpoints were patient-reported health status, intraocular pressure, and incremental cost-effectiveness ratio per quality-adjusted life-year gained 36 months after treatment. Analysis was by intention to treat. This study is registered, number ISRCTN44464607.

Findings Of 419 participants enrolled, 155 had primary angle closure and 263 primary angle-closure glaucoma. 208 were assigned to clear-lens extraction and 211 to standard care, of whom 351 (84%) had complete data on health status and 366 (87%) on intraocular pressure. The mean health status score (0·87 [SD 0·12]), assessed with the European Quality of Life-5 Dimensions questionnaire, was 0·052 higher (95% CI 0·015–0·088, $p=0\cdot005$) and mean intraocular pressure (16·6 [SD 3·5] mm Hg) 1·18 mm Hg lower (95% CI –1·99 to –0·38, $p=0\cdot004$) after clear-lens extraction than after standard care. The incremental cost-effectiveness ratio was £14284 for initial lens extraction versus standard care. Irreversible loss of vision occurred in one participant who underwent clear-lens extraction and three who received standard care. No patients had serious adverse events.

Interpretation Clear-lens extraction showed greater efficacy and was more cost-effective than laser peripheral iridotomy, and should be considered as an option for first-line treatment.



Lancet 2016; 388: 1389–97

See Editorial page 1349

See Comment page 1352

Centre for Public Health,
Queen's University Belfast,
Belfast, UK

(Prof A Azuara-Blanco PhD);
School of Medicine, University
of St Andrews, St Andrews, UK
(J Burr MD); Health Services
Research Unit

(Prof C Ramsay PhD,
D Cooper PhD, G Scotland PhD,
C Cochrane MSc,

Prof J Norrie PhD), Health
Economics Research Unit
(G Scotland, M Javanbakht PhD),

and Centre for Health Care
Randomised Trials

(Prof J Norrie), University of
Aberdeen, Aberdeen, UK; NIHR
Biomedical Research Centre,
Moorfields Eye Hospital and
University College London, UK

(Prof P J Foster PhD); and
Johns Hopkins Wilmer Eye
Institute, Baltimore, MD, USA
(Prof D S Friedman PhD)

Early lens extraction with intraocular lens implantation for the treatment of primary angle closure glaucoma: an economic evaluation based on data from the EAGLE trial

Mehdi Javanbakht,¹ Augusto Azuara-Blanco,² Jennifer M Burr,³ Craig Ramsay,⁴ David Cooper,⁴ Claire Cochran,⁴ John Norrie,⁴ Graham Scotland^{1,4}

Conclusions: We find that lens extraction has a 67–89% chance of being cost-effective at 3 years and that it may be cost saving by 10 years.

Subsequent Receipt of Interventions for Glaucoma Among a Nationwide Sample of Patients Who Underwent Laser Peripheral Iridotomy

Surbhi Bansal¹, S. Asha Balakrishnan¹, Taylor Blachley¹, Jennifer S. Welzer¹, Paul P. Lee^{1,2}, and Joshua D. Stein^{1,2}

Conclusion—Most patients undergoing bilateral LPIs received no pre- or post-LPI glaucoma-medication-class prescriptions and had no cataract or additional glaucoma surgery within 2 years after LPIs. Clinicians should alert black or older patients, and those already taking glaucoma medications before the procedure of their higher odds of requiring medications afterward.

Organizing Angle Closure

Angle-Closure Disease Staging and Treatment

Disease Stage	Associated Signs	Recommended Treatment
PACS (primary angle closure suspect)	Appositional contact but no PAS; normal IOP and optic nerve. Trabecular meshwork at risk.	LPI? Or observation?
PAC (primary angle closure)	High IOP and/or PAS (i.e., trabecular meshwork dysfunction) but no optic nerve damage.	Phaco if IOP is above 30 mmHg (as per the EAGLE study)
PACG (primary angle-closure glaucoma)	High IOP and/or PAS with optic nerve damage.	Phaco, with or without trabeculectomy or GDD

<https://www.reviewofophthalmology.com/article/the-asymptomatic-pac-suspect-lpi-or-no-lpi>

- Acute angle closure?

Pre-Operative Exam

Informed consent*

- Educate the patient on what the procedure is, why we are doing it, what outcome to expect, risks and benefits of doing/not doing the procedure, alternative procedures, and complications

Pre-Operative Exam

Only doing procedure on 1 eye per visit

Instill 1 gtt of 1%, 2% pilocarpine in surgical eye...4%?

Instill 1 gtt of brimonidine in surgical eye

Instill 1 gtt of proparacaine in each eye

Energy settings?

Energy Settings

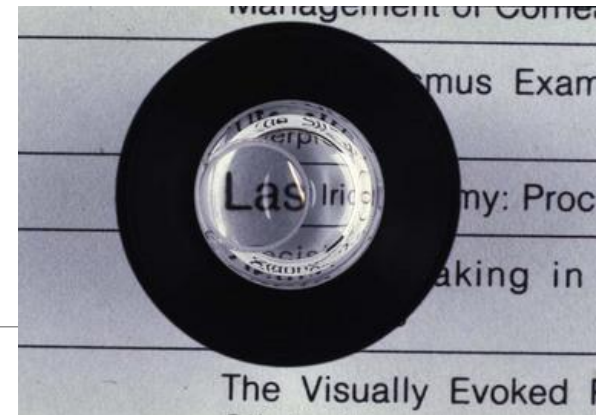
Argon/Green/532nm Laser

- Typically not used
- Can still use or use to pre-treat
- May provide utility regarding darker iris pigmentation
- Coagulative
- Spot size, 50um
- Duration, 0.1s
- Power, 300-1200mW

Nd:YAG 1064nm Laser

- More commonly used
- May have less utility regarding darkly pigmented eyes, although still generally used more often than green laser
- Photodisruptive
- Offset, zero microns, can consider slight defocus
- Spot size, fixed ~8um
- Duration, 3-7ns
- Energy, various accepted "norms", may say 1-6mJ or 2-6mJ, we usually recommend **3.0-6.0mJ**
- Pulse, 1-3

Procedure



Locate appropriate position for procedure

- Ideally an iris crypt at the 11:00, 1:00, 3:00, or 9:00 position

Align HeNe beams, consider slight inward defocus

Proceed deeper into same area until through iris with adequate sized PI

- About 150-200um size is required for therapeutic effect, we recommend about 0.5

Post-Operative Exam

Encourage patient procedure went well

Instill 1 gtt of brimonidine in post surgical eye

Recheck IOP 30 mins – 1 hr after procedure

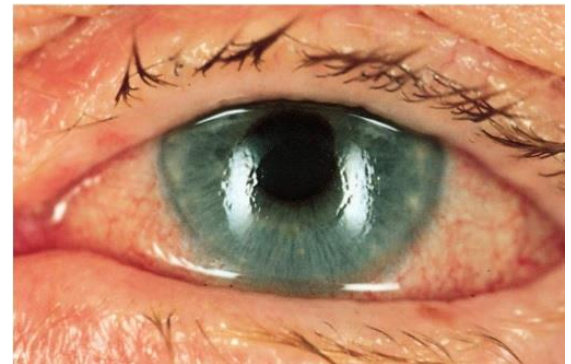
Rx prednisolone acetate QID in post surgical eye for 1 week

Re-educate on signs and symptoms of complications

Follow up in 1 week for evaluation of post surgical eye, and procedure fellow eye if appropriate

Case 1

- 50 year old WF presents with acute unilateral pain for 1.5 days
- Signs and symptoms of angle closure present
- IOP 49 mmHG
- Gonioscopy revealed closure to SL in 3 quadrants
 - Indentation gonioscopy indicates significant pupillary block component
 - Fellow eye is closure suspect with pupillary block component



<https://www.tuyenlab.net/2018/03/emergency-atlas-of-acute-angle-closure.html>

Case 1

- Discussed options, patient refuses clear lens extraction and did not have surgeon available anyways
 - Patient was extremely nervous and had difficulty maintaining fixation
 - 5mg diazepam given

- Topically lowered IOP to below 40

- LPI relieved closure
 - 20 shots, 59.17mJ total energy

- She remains open and stable without topical therapy, prophylactic LPI done fellow eye

Case 2

- 62 year old WF presents with acute unilateral pain for 1 week
 - With intermittent episodes increasing their frequency for about 2 months prior to this severe episode
- Signs and symptoms of angle closure present
- IOP 54 mmHg
- Gonioscopy revealed closure to SL in 4 quadrants with a sliver of varying ATM/PTM in 1 of the quadrants
 - Indentation gonioscopy indicates trace pupillary block component, “double hump observed in ~2 quadrants”
 - Fellow eye closure suspect with mild pupillary block component and combined plateau configuration with questionable “double hump”



<http://www.eyerounds.org/atlas/pages/Peripheral-anterior-synechiae.htm>

Case 2

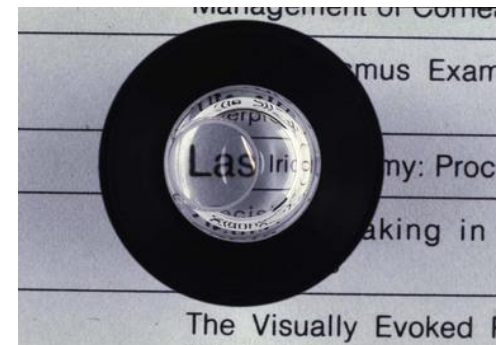
- Patient has mild nuclear sclerosis, but would prefer to defer lens extraction if possible due to other surgeries she has scheduled
- Topically lowered IOP to 43 mmHg, given two 250 mg acetazolamide and performed LPI
- LPI relieved acute closure episode
 - 17 shots, 51.24 mJ total energy
- After patient stabilized, gonioscopy showed approximately 2 quadrants of PTM visible

Case 2

- Patient followed up 2 days later and remained stable only maintaining topical therapy
- She missed her 1 week follow up
- Presented 1.5 weeks later with recurrence of symptoms
- PTM only visible in 1 quadrant on gonioscopy and IOP 34 mmHg
- Increased topical therapy with close follow ups while awaiting clear lens surgery
 - Prophylactic LPI conducted in fellow eye

Case 3

- 68 year old WF presents to local emergency room with severe unilateral pain for 2 days
- IOP was not checked
- She was told she had an infection and they scheduled her an evaluation in our clinic, where she presented 3 weeks later
 - Showed up at 10:30 AM
- Still in intense pain with 20/400 vision
- Signs and symptoms of angle closure



<http://ourgsc.blogspot.com/2019/08/peripheral-laser-iridotomy-guest-author.html>

Case 3

- IOP 61 mmHg
- Corneal edema and bullae limit gonioscopy views, but no structures visible, no NVA/NVI visible, no retinal vein or artery occlusion
 - Response to indentation difficult to appreciate
 - Fellow eye is suspect for closure with prominent plateau iris configuration
- Patient has mild lens changes OU and is amenable to any treatment possible to help her problem eye and protect her non-involved eye
- IOP was attempted to be lowered topically to no avail

Case 3

- Patient was given two 250 mg tablets of acetazolamide, which she vomited
- Given 4mg of ondansetron (Zofran), and 500 mg more of acetazolamide
 - Which she kept down for about 30 minutes and eventually vomited again
- IOP was lowered to 55 mmHg
- Despite probable need for lens extraction due to likely 360 degree synechial closure from prolonged apposition
 - LPI was conducted in emergent scenario to attempt to provide any relief
 - Also surgeon consult requested we stabilize eye and clear cornea prior to cataract surgery

Case 3

- LPI was able to get through iris, but did not relieve closure attack
 - 59 shots, 295.37 mJ total energy

- Considered anterior chamber paracentesis with 30g needle attached to plunger-less syringe vs. our hospital emergency room for IV acetazolamide
 - Opted for the IV acetazolamide

- IOP lowered to 39 mmHg
 - Kept topicals going
 - Could tolerate orals at this point, so kept those going, 250 mg BID
 - Seeing that patient was responding to therapy, and cataract surgeons were not willing to perform surgery with condition of the cornea
 - I went home (8:30 PM), and followed up with patient at 8:00 AM next morning

Case 3

- IOP 20 mmHg next morning
- Prophylactic LPI performed in fellow eye, confirmed plateau iris
- Kept topicals and orals going
 - Kept patient stable over next 2 weeks until cornea and bullae improved to a point where ophthalmology felt comfortable operating
- Cataract extraction and Ahmed valve successfully completed
- Patient remains stable off topicals and orals, vision remains 20/400

Contraindications

- Prominent unclear media (corneal edema, uveitis, etc.)
- Chamber is too shallow
- Active uveitis
- Uncooperative patients

Does Position Matter?

Dysphotopsia after temporal versus superior laser peripheral iridotomy: a prospective randomized paired eye trial

Vanessa Vera ¹, Abdulla Naqi ¹, Graham W Belovay ¹, Devesh K Varma ², Iqbal Ike K Ahmed ³

Affiliations + expand

PMID: 24531024 DOI: 10.1016/j.ajo.2014.02.010

Abstract

Purpose: To determine if the location of neodymium:yttrium-aluminum-garnet laser peripheral iridotomy (LPI) is related to the occurrence of postoperative visual dysphotopsia.

Design: Randomized, prospective, single-masked, paired-eye comparative clinical trial.

Methods: setting: Private subspecialty clinic in Mississauga, Canada. study population: Patients with primary angle closure or primary angle-closure suspects were recruited and randomized to receive LPI temporally in one eye and superiorly in the other. Patients were masked to the location of treatment in each eye. intervention: Temporal or superior LPI. main outcome measures: Occurrence of new-onset linear dysphotopsia. Other visual disturbances also were assessed using a questionnaire before and 1 month after intervention. Secondary outcome measures included eyelid position, laser parameters, and any intraoperative complications.

Results: A total of 208 patients were recruited to the study, of which 169 (84%) completed it. New-onset linear dysphotopsia was reported in 18 (10.7%) eyes with superior LPI versus 4 (2.4%) eyes with temporal LPI ($P = .002$). Eleven eyes (6.5%) with superior LPI reported linear dysphotopsia despite complete eyelid coverage of the iridotomy. No significant differences were found with other visual disturbances between them. There was more pain experienced by the temporal LPI (2.8 ± 2.2 vs 2.1 ± 2.0 ; $P = .001$), despite no difference in laser energy or number of shots. Intraoperative rates of hemorrhage were similar (8.9% vs 10.1%; $P = .71$).

Conclusions: Temporal placement of LPI is safe and was found to be less likely to result in linear dysphotopsia as compared with superior placement. Temporal iris therefore may be considered a preferred location for LPI.

Comparison of New Visual Disturbances after Superior versus Nasal/Temporal Laser Peripheral Iridotomy: A Prospective Randomized Trial

Kavitha Srinivasan ¹, Nazlee Zebardast ², Palaniswamy Krishnamurthy ¹, Mohideen Abdul Kader ³, Ganesh V Raman ⁴, Sharmila Rajendrababu ⁵, Rengaraj Venkatesh ¹, Pradeep Y Ramulu ⁶

Affiliations + expand

PMID: 29096997 DOI: 10.1016/j.ophtha.2017.09.015

Abstract

Purpose: To determine whether laser peripheral iridotomy (LPI) location affects postoperative dysphotopsia symptoms.

Design: Multicenter, randomized, prospective, single-masked trial.

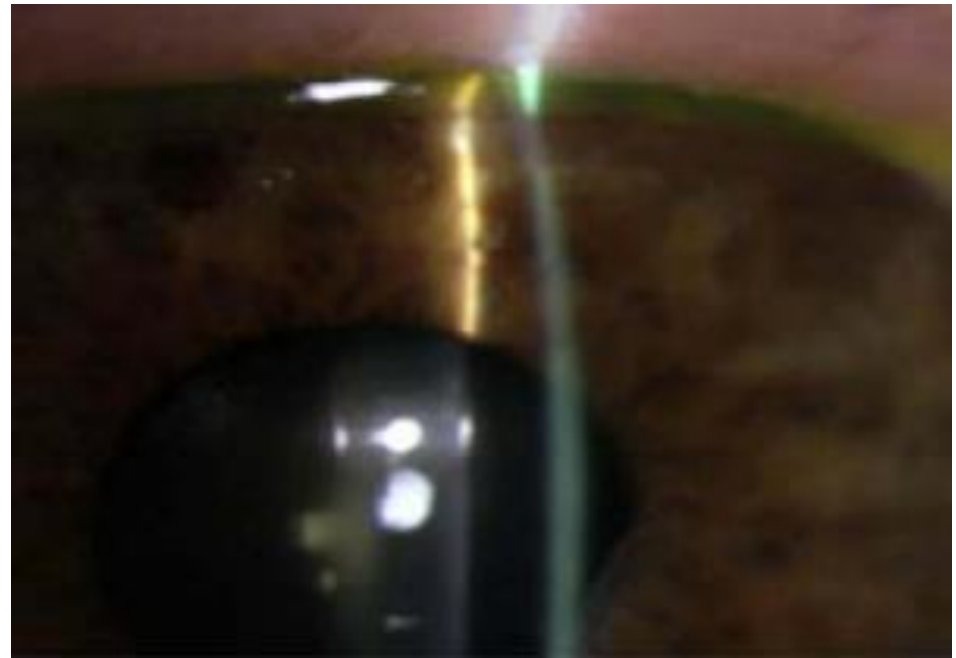
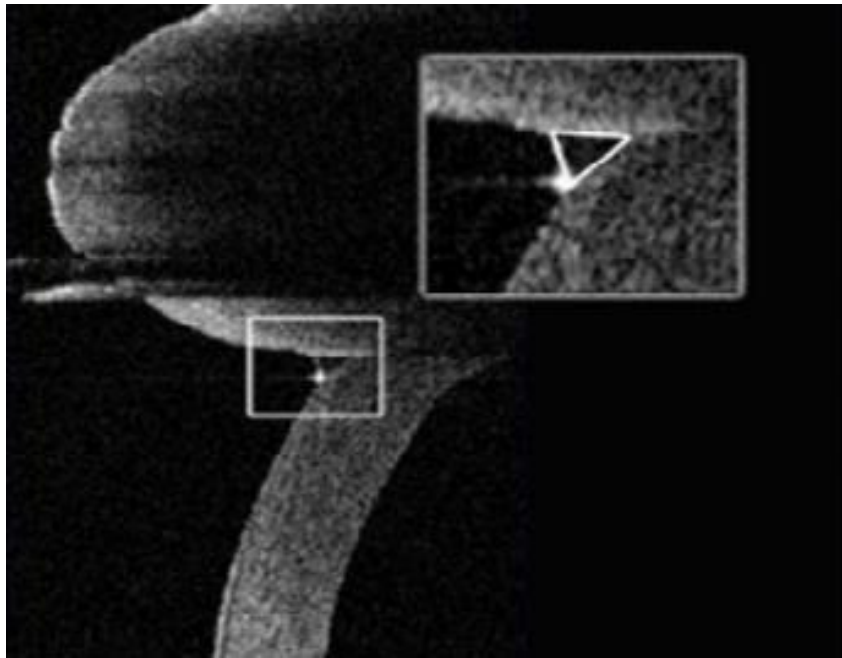
Participants: Five hundred fifty-nine South Indian patients 30 years of age or older diagnosed as primary angle-closure suspects (PACs) or with primary angle closure (PAC) or primary angle-closure glaucoma (PACG) in both eyes.

Methods: Patients were randomized to either bilateral superior or bilateral nasal/temporal LPI. Occurrence of new visual disturbances was evaluated before and 2 weeks after LPI using a questionnaire based on the 7-item dysphotopsia symptoms described by Spaeth et al.

Main outcome measures: New-onset dysphotopsia symptoms.

Results: Superior LPI ($n = 285$) and nasal/temporal LPI ($n = 274$) patients were matched for age ($P = 0.6$), gender ($P = 0.7$), and distribution of PACs versus PAC or PACG ($P = 0.7$). Similar initial laser energy settings were used in both groups ($P = 0.3$), although superior LPIs required more shots ($P = 0.006$) and greater total energy ($P < 0.001$) than nasal/temporal LPIs. No significant differences in postoperative anterior chamber reaction ($P = 0.7$) or LPI area ($P = 0.9$) were noted between the 2 groups. No group differences were noted regarding the proportion of patients demonstrating 1 or more dysphotopsia symptoms before LPI (15.8% for superior vs. 13.9% for nasal/temporal; $P = 0.1$) or any individual dysphotopsia symptom ($P > 0.2$ for all). After LPI, 8.9% of all patients reported 1 or more new symptoms, the most common consisting of linear dysphotopsias, glare, and blurring in 2.7%, 4.3%, and 4.3% of patients, respectively. Patients undergoing superior LPI were not more likely to describe the new onset of 1 or more dysphotopsia symptoms as compared with patients undergoing nasal/temporal LPI (8.4% vs. 9.5%; $P = 0.7$), nor did the frequency of any new individual symptoms differ by group ($P \geq 0.3$ for all). In multivariate logistic regression analysis, neither LPI location nor LPI area nor total laser energy predicted higher odds of new postoperative dysphotopsias ($P > 0.1$ for all).

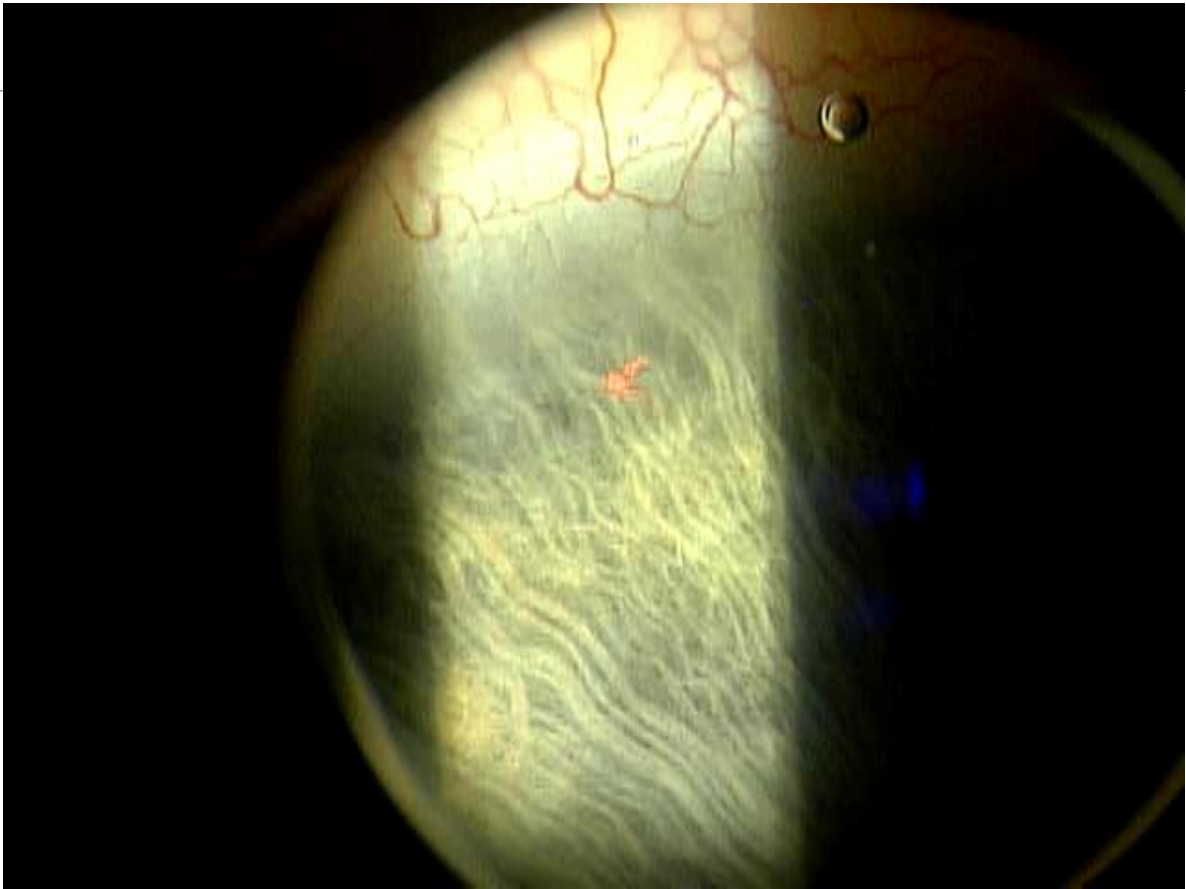
Conclusions: Laser peripheral iridotomy likely is safe with respect to visual dysphotopsias regardless of location, LPI size, and amount of laser energy used.

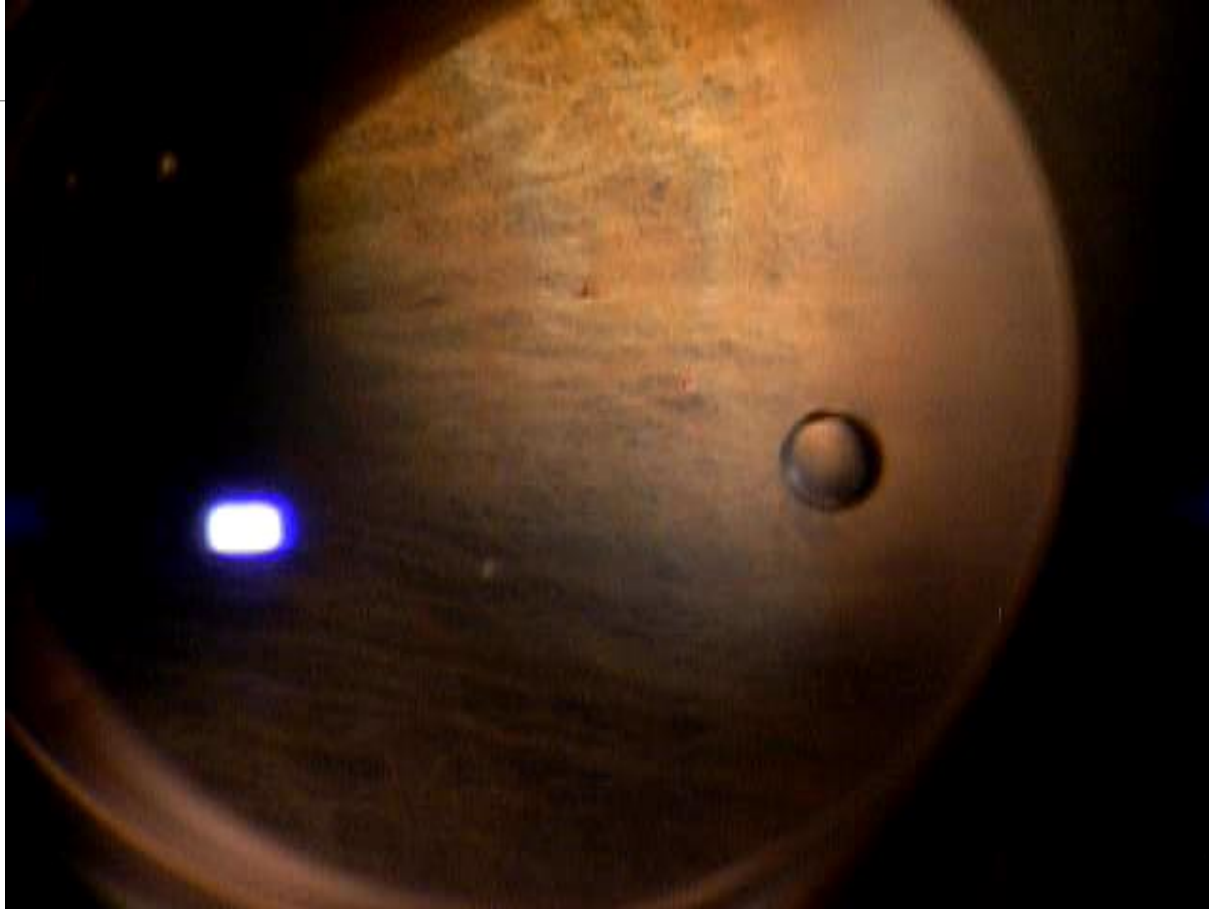


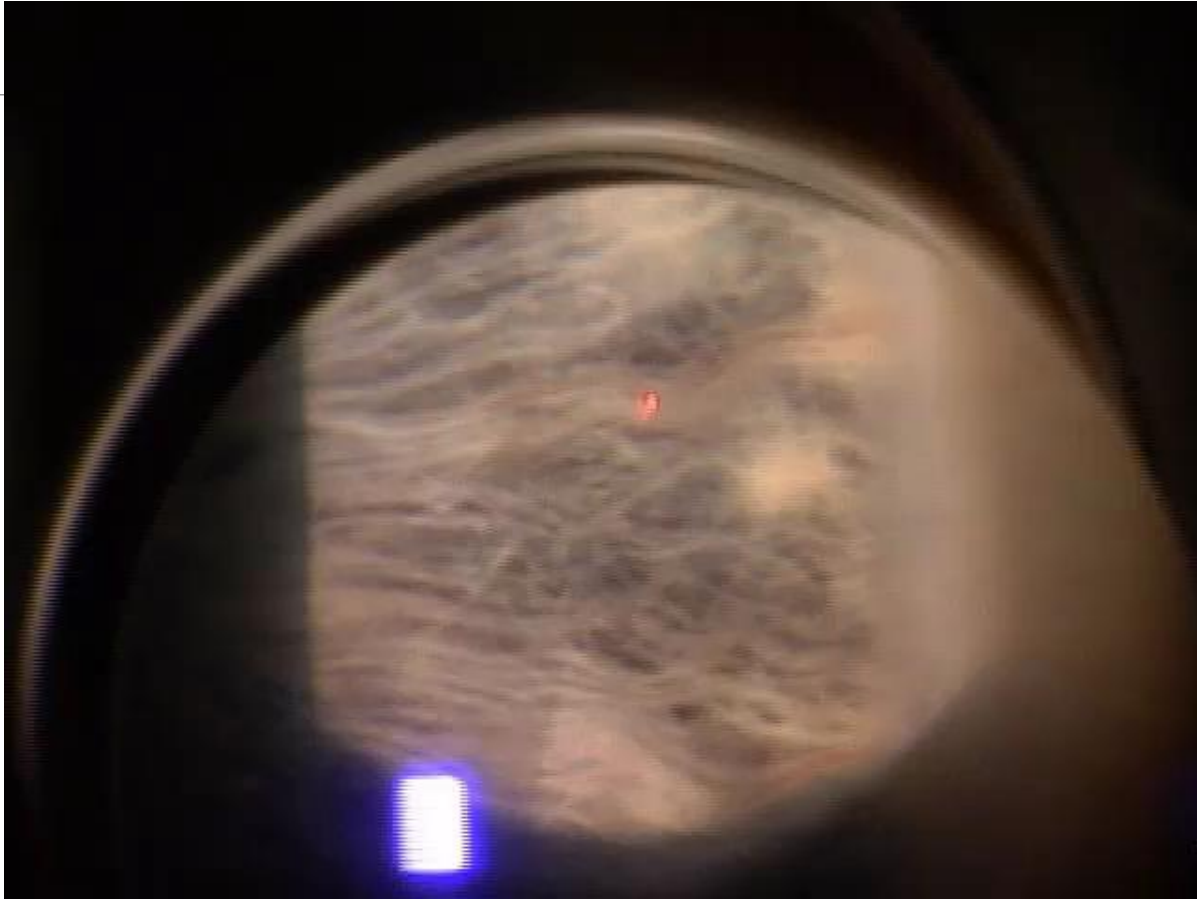
Lighthizer, Nathan. "Laser Therapy in Narrow Angles, Angle Closure". NSUCO Advanced Procedures Course. Philadelphia 2019.

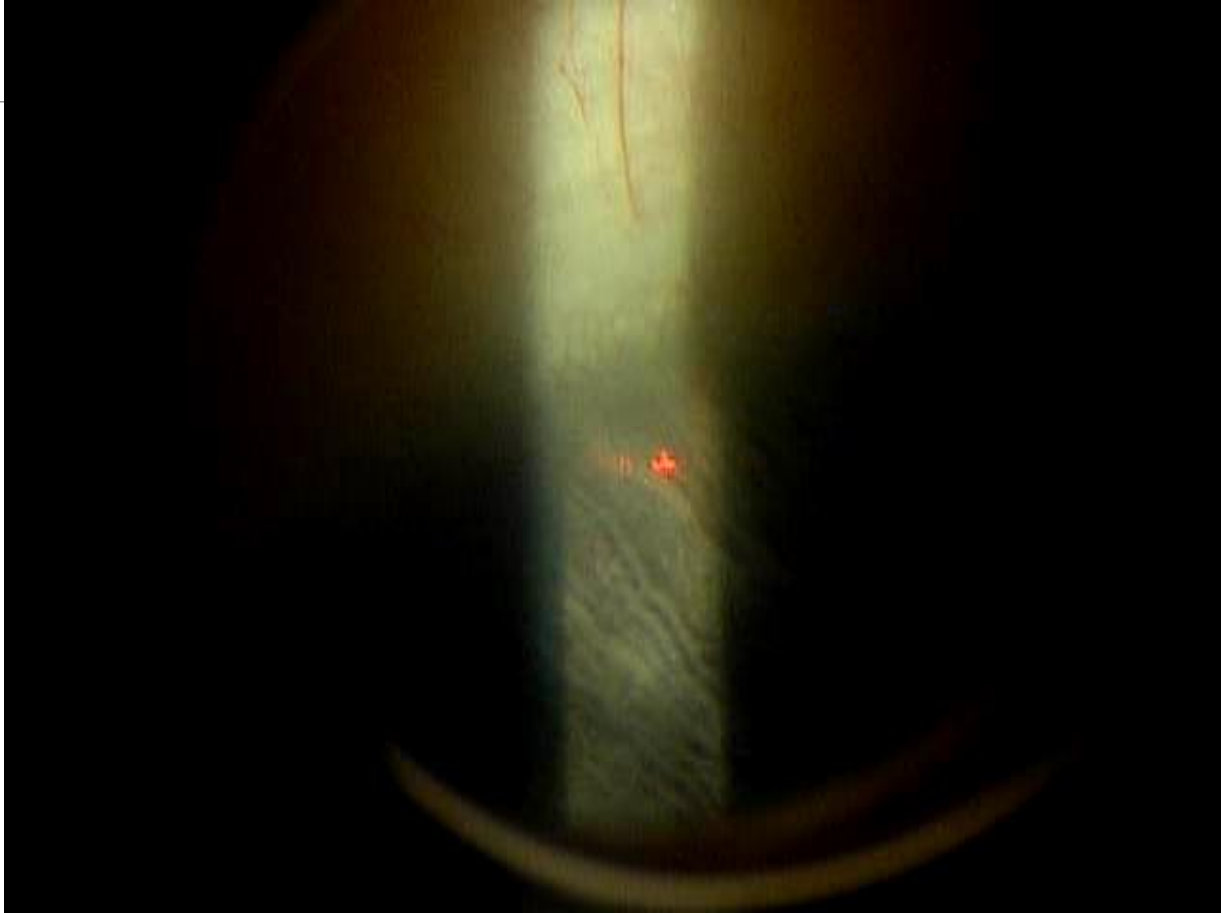Complications

- IOP spike and inflammation most common
- Hyphema
- Dysphotopsia
- Synechia, correctopia, floaters, monocular diplopia, retinal detachment









Global Period

- 10 days

Physician Fee Schedule

- CMS.gov
- CPT 66761

- Non-Facility Price
 - Varies depending on change in RVUs, conversion factors, and geography
 - Averages about \$350.00

- Facility Price
 - Same variable factors
 - Averages about \$260.00

Questions?

works cited

- Allingham, R. Rand. *Shields Textbook of Glaucoma*. Wolters Kluwer, 2021.
- Azuara-Blanco, Augusto. "The Effectiveness of Early Lens Extraction with Intraocular Lens Implantation for the Treatment of Primary Angle Closure Glaucoma: a Randomised Controlled Trial (EAGLE)." *Http://Isrctn.org/*>, 2013, doi:10.1186/isrctn44464607.
- Bansal, Surbhi, et al. "Subsequent Receipt of Interventions for Glaucoma Among a Nationwide Sample of Patients Who Underwent Laser Peripheral Iridotomy." *American Journal of Ophthalmology*, vol. 160, no. 2, 2015, doi:10.1016/j.ajo.2015.04.031.
- Coh, Paul, et al. "Lens Position Parameters as Predictors of Intraocular Pressure Reduction After Cataract Surgery in Glaucomatous Versus Nonglaucomatous Eyes." *Investigative Ophthalmology & Visual Science*, vol. 57, no. 6, 2016, p. 2593., doi:10.1167/iovs.16-19384.
- Desai, Manishi. "Plateau Iris." *EyeWiki*, 4 Apr. 2020, eyewiki.aao.org/Plateau_Iris.
- Ertel, Monica. "Aqueous Misdirection." *EyeWiki*, 18 May 2020, eyewiki.aao.org/Aqueous_misdirection.
- H. George Tanaka, MD. "The Asymptomatic PAC Suspect: LPI or No LPI?" *Review of Ophthalmology*, 25 Sept. 2018, www.reviewofophthalmology.com/article/the-asymptomatic-pac-suspect-lpi-or-no-lpi.
- Javanbakht, Mehdi, et al. "Early Lens Extraction with Intraocular Lens Implantation for the Treatment of Primary Angle Closure Glaucoma: an Economic Evaluation Based on Data from the EAGLE Trial." *BMJ Open*, vol. 7, no. 1, 2017, doi:10.1136/bmjopen-2016-013254.
- Jiang, Yuzhen, et al. "Longitudinal Changes of Angle Configuration in Primary Angle-Closure Suspects: the Zhongshan Angle-Closure Prevention Trial." *Ophthalmology*, U.S. National Library of Medicine, Sept. 2014, www.ncbi.nlm.nih.gov/pmc/articles/PMC4624262/.
- Kahook, George. "Iridoplasty." *Glaucoma Today*, Bryn Mawr Communications, 2006, glaucomatoday.com/articles/2006-july-aug/0706_10.html.
- Kam, Jason, et al. "Resident-Performed Laser Peripheral Iridotomy in Primary Angle Closure, Primary Angle Closure Suspects, and Primary Angle Closure Glaucoma." *Clinical Ophthalmology*, Volume 11, 2017, pp. 1871–1876., doi:10.2147/oph.s148467

works cited

- Lavanya R;Baskaran M;Kumar RS;Wong HT;Chew PT;Foster PJ;Friedman DS;Aung T; "Risk of Acute Angle Closure and Changes in Intraocular Pressure after Pupillary Dilation in Asian Subjects with Narrow Angles." *Ophthalmology*, U.S. National Library of Medicine, 2012, pubmed.ncbi.nlm.nih.gov/22118999/.
- Lighthizer, Nathan. "Laser Therapy in Narrow Angles, Angle Closure". NSUCO Advanced Procedures Course. Philadelphia 2019.
- Melese, Ephrem, et al. "Comparing Laser Peripheral Iridotomy to Cataract Extraction in Narrow Angle Eyes Using Anterior Segment Optical Coherence Tomography." *PLOS ONE*, vol. 11, no. 9, 2016, doi:10.1371/journal.pone.0162283.
- Silva, Andre. "Laser Peripheral Iridotomy." *EyeWiki*, 4 Apr. 2020, eyewiki.aao.org/Laser_Peripheral_Iridotomy.
- Srinivasan K;Zebardast N;Krishnamurthy P;Abdul Kader M;Raman GV;Rajendrababu S;Venkatesh R;Ramulu PY; "Comparison of New Visual Disturbances after Superior versus Nasal/Temporal Laser Peripheral Iridotomy: A Prospective Randomized Trial." *Ophthalmology*, U.S. National Library of Medicine, 2017, pubmed.ncbi.nlm.nih.gov/29096997/.
- Tsui, Jolly L., et al. "The Role of Lens Extraction in Glaucoma Management." *Annals of Translational Medicine*, vol. 8, no. 22, 2020, pp. 1550–1550., doi:10.21037/atm-20-3251a.
- Vera V;Naqi A;Belovay GW;Varma DK;Ahmed II; "Dysphotopsia after Temporal versus Superior Laser Peripheral Iridotomy: a Prospective Randomized Paired Eye Trial." *American Journal of Ophthalmology*, U.S. National Library of Medicine, 2014, pubmed.ncbi.nlm.nih.gov/24531024/.
- Yusuf, Imran H, et al. "Silicone Oil Pupil Block Glaucoma in a Pseudophakic Eye." *BMJ Case Reports*, BMJ Publishing Group, 23 Sept. 2014, www.ncbi.nlm.nih.gov/pmc/articles/PMC4173143/.

works cited

- Abo-Shasha, Rami. "Management of Pupillary Seclusion and Occlusion of an Iris Enclaved Intraocular Lens." *Define_me*, [https://www.canadianjournalofophthalmology.ca/article/S0008-4182\(20\)30631-1/fulltext](https://www.canadianjournalofophthalmology.ca/article/S0008-4182(20)30631-1/fulltext).
- "Academy." *Heidelberg Engineering Academy*, https://academy.heidelbergengineering.com/course/view.php?id=516&he_locale=en_US&he_country=US&he_site=us.
- "Angle Closure Can Be Missed Using the Van Herick Method." *Dr Vincent Lee*, <https://www.drvincentlee.com.au/news/angle-closure-can-be-missed-by-van-herick-technique>.
- *Anterior Segment Oct: Precision Angle Imaging*. https://assets.bmctoday.net/glaucomatoday/pdfs/0319GT_F1_Chopra.pdf.
- Brinton, Jason. "FDA Approves Evo Visian Lens." *Healio*, <https://www.healio.com/news/ophthalmology/20220328/fda-approves-evo-visian-lens>.
- Debrouwere, Veroniek, et al. "Outcomes of Different Management Options for Malignant Glaucoma: A Retrospective Study - Graefe's Archive for Clinical and Experimental Ophthalmology." *SpringerLink*, Springer-Verlag, 20 Aug. 2011, <https://link.springer.com/article/10.1007/s00417-011-1763-0/figures/4>.
- "Eyereum Menu." *EYEREUM*, <https://eyereum.com/en/center/icl>.
- "Gonioscope GS-1: Retina & Glaucoma: Nidek Co.,Ltd.." *Eye & Health Care NIDEK CO., LTD.*, https://www.nidek-intl.com/product/ophthalptom/diagnostic/dia_retina/ga-1.html.
- MD, Wallace L M Alward, and Reid A Longmuir MD. "Abnormalities Associated with a Closed Angle." *American Academy of Ophthalmology*, 24 June 2021, <https://www.aao.org/disease-review/abnormalities-associated-with-closed-angle>.
- MD, Wallace L M Alward, and Reid A Longmuir MD. "The Normal Angle." *American Academy of Ophthalmology*, 24 June 2021, <https://www.aao.org/disease-review/the-normal-angle>.
- Sunjita Radhakrishnan, MD. "Diagnosing Angle Closure: Gonioscopy vs. Oct." *Review of Ophthalmology*, 5 Apr. 2019, <https://www.reviewofophthalmology.com/article/diagnosing-angle-closure-gonioscopy-vs-oct>.
- Themes, UFO. "17." *Ento Key*, 2 Sept. 2016, <https://entokey.com/17-2/>.
- Ursea, Roxana. *Ultrasound Biomicroscopy Images of Malignant Glaucoma (a ...* https://www.researchgate.net/figure/Ultrasound-biomicroscopy-images-of-malignant-glaucoma-A-Anterior-segment-in-horizontal_fig4_42372682.
- Usmani, Nazmi. "Glaucoma Specialist Blog: 'The Glog.'" *GLAUCOMA SPECIALIST BLOG: "THE GLOG"*, 16 June 2019, <http://ourgsc.blogspot.com/2019/06/malignant-glaucoma-guest-author-nazmi.html>.
- Yusuf, Imran H, et al. "Silicone Oil Pupil Block Glaucoma in a Pseudophakic Eye." *BMJ Case Reports*, BMJ Publishing Group, 23 Sept. 2014, <https://www.ncbi.nlm.nih.gov/pmc/articles/PMC4173143/>.