



**EyeSystems**

- Mary E. Schmidt, ABOC, CPO
- Mary@EyeSystems.info
- www.EyeSystems.info

No audio or video recording permitted

---

---

---

---

---

---


---

---

1

**EyeSystems**

### What's In My Eye? Emergency or Urgency? Common Diseases and Disorders



No audio or video recording of presentation allowed

---

---

---

---

---

---

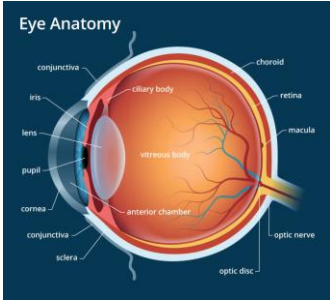
---

---

2

**EyeSystems**

### Basic Structure



**Eye Anatomy**

- conjunctiva
- iris
- lens
- pupil
- cornea
- conjunctiva
- sclera
- ciliary body
- vitreous body
- anterior chamber
- choroid
- retina
- macula
- optic nerve
- optic disc

---

---

---

---

---

---

---


---

3

*EyeSystems*  
60

### Eyelid

- Stye, Hordeolum, Chalazion
  - Symptoms
  - Is it contagious?
- Foreign body
  - Symptoms
  - Your reaction



---

---

---

---

---

---

---

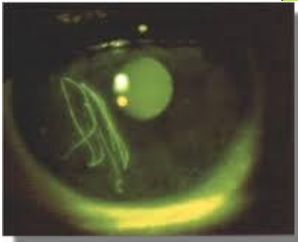
---

4

*EyeSystems*  
60

### Cornea

- Abrasion – is a scratch
  - Symptoms
- Reaction time?



---

---

---

---

---

---

---

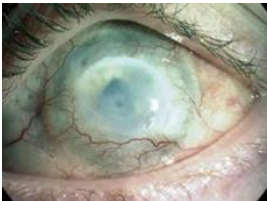
---

5

*EyeSystems*  
60

### Cornea

- Chemical burns
  - Acid burns
  - Alkali burns
    - Delayed reaction
- Symptoms
- Actions to take?



---

---

---

---

---

---

---

---

6

*EyeSystems*  
60

## Cornea

- Foreign bodies
  - Causes
  - Worker's Comp
  - Your reaction




---

---

---

---

---

---

---

---

7

*EyeSystems*  
60

## Lasik surgery

### LASIK SURGERY STEPS



1. Numbing drops are applied to the eyes
2. Incision is made creating a corneal flap
3. Excimer laser reshapes the cornea
4. The incision heals on its own

● [https://www.youtube.com/watch?v=UezYWOqPQ\\_Q](https://www.youtube.com/watch?v=UezYWOqPQ_Q)

---

---

---

---

---

---

---


---

8

*EyeSystems*  
60

## Conjunctiva

- Conjunctivitis - an inflammation of the conjunctiva.
  - Also known as \_\_\_\_\_?
  - How can you get it?
  - Is it contagious?




---

---

---

---

---

---

---


---

9

*EyeSystems*  
60

## Conjunctiva

- Subconjunctival hemorrhage is blood that is located between the conjunctiva and the underlying sclera.
- Causes:
  - Sneezing
  - Coughing
  - Straining/vomiting
  - Increasing the pressure in the veins of the head, as in weightlifting
  - Eye rubbing
  - Certain infections where a virus or a bacteria weaken the walls of small blood vessels under the conjunctiva
  - Medical disorder causing bleeding or inhibiting normal clotting.




---

---

---

---

---

---

---



---

10

*EyeSystems*  
60

## Conjunctiva

- Pinguecula -is a yellowish, slightly raised thickening of the conjunctiva on the white part of the eye (sclera), close to the edge
  - Emergency or Urgency?
- Pterygium - most often refers to a benign growth of the conjunctiva. It is associated with and thought to be caused by ultraviolet-light exposure, low humidity, and dust.
  - Cause blindness?


---

---

---

---

---

---

---

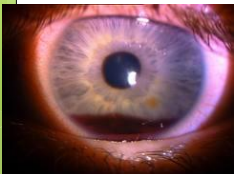
---

11

*EyeSystems*  
60

## Anterior Chamber

- Hyphema – is a collection of blood in the anterior chamber.
- The blood may cover part or all of the iris and the pupil, and may partly or totally block vision in that eye.
- Usually caused by trauma to the eye, though other conditions may cause hyphema as well.
- Usually goes away on its own.




---

---

---

---

---

---

---

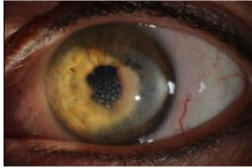
---

12

*EyeSystems*  
60

### Iris

- Iritis is a painful inflammation of the iris of the eye.
- Causes: Largely unknown.
- Treatment: Medication




---

---

---

---

---

---

---

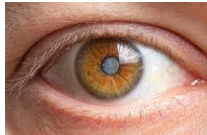---

13

*EyeSystems*  
60

### Crystalline Lens

- Cataracts - A cataract is a clouding of the lens in the eye that affects vision. Most cataracts are related to aging.
- Treatments?




---

---

---

---

---

---

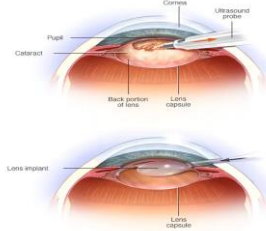
---

---

14

*EyeSystems*  
60

### Cataract Surgery



- <https://www.youtube.com/watch?v=Go82c4f1emc>
- <https://www.youtube.com/watch?v=MqwyoXBwFSI>

---

---

---

---

---

---

---


---

15

*EyeSystems*

## Vitreous Body - Retina

- Floaters are caused by age-related changes that occur as the vitreous inside your eyes becomes more liquid. Microscopic fibers within the vitreous tend to clump together and can cast tiny shadows on your retina.
- Dangerous?
- Sight threatening?



16

---

---

---

---

---

---

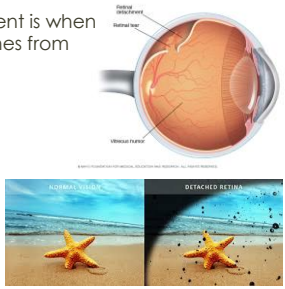
---

---

*EyeSystems*

## Vitreous Body - Retina

- Retinal detachment is when the retina detaches from the...?
- Treatment
- Vision restored?



17

---

---

---

---

---

---

---

---

*EyeSystems*

## EMERGENCIES

**Conditions requiring patients to be seen immediately, within hours, or on the same day:**

1. **Chemicals or other toxins splashed into the eye within the last hour.** The patient should be instructed to irrigate immediately and profusely with clean water if saline is not available. They should not put any drops into their eyes until they have been examined and the chemical and any damage to the eye have been clearly determined.
2. **Sudden loss or decrease of vision, or the appearance of a cloudy veil in front of the eye.** This could be a central retinal artery occlusion, in which case the patient must be seen within an hour of occurrence. It could also be a sign of retinal detachment.
3. **Penetrating ocular injury.** The neurosurgeon must be determined immediately in order to know whether to have the patient come into the office or to send them directly to an emergency service.
4. **Forceful trauma to the eye or adnexa.** This may result in a blowout fracture of the orbit (which may cause other problems in the sinuses), a retinal detachment, or hyphema (blood in the anterior chamber).
5. **Sudden onset of halos around lights, especially if associated with a red, painful eye or burn.** This could be an acute angle closure attack which should be treated immediately.
6. **Sudden onset of persistent, severe pain in or around the eye, or severe pain on movement of the eye.** This could be orbital cellulitis, a severe infection that should be treated quickly to avoid further complications.
7. **Foreign body in the eye, or the suspicion of such.** Removing a foreign body soon after its introduction can prevent further damage to the eye.
8. **Sudden onset of flashing lights and/or floaters.** This could be a vitreous detachment, a retinal detachment, or a symptom of migraine.
9. **Sudden onset of diplopia (double vision, not blur).** This could be the result of a neurological problem or a mass in the brain, and after initial examination, further testing may be ordered.
10. **Sudden onset of drooping eyelid.** Again, this could be the result of a neurological problem.
11. **Sudden onset of persistent red eye, with or without pain, visual disturbance or tearing.** This could be a sub-conjunctival hemorrhage, an infection, or an inflammation. Treatment depends on the cause and can vary from passive (the hemorrhage will resolve with time) to aggressive use of the appropriate pharmaceutical agent.



18

---

---

---

---

---

---

---


---

*EyeSystems*  
60

### URGENCIES

Patients who should be seen sooner than usual, as soon as possible without true emergency status.

1. Blurred vision which has developed over time. This may be considered an emergency depending on symptoms, so careful triage is necessary to determine the appropriate course of action.
2. Contact lens wearers with sudden problems of vision, discomfort, or eye appearance. The patient should be told to remove the lenses until he or she can be thoroughly examined and the problem determined.
3. Lost or broken eyewear or contact lenses. This may seem like a critical emergency to some patients, and appropriate concern and attention must be paid to resolve their problem.



19

---

---

---

---

---

---

---

---

*EyeSystems*  
60



20

---

---

---

---

---

---

---

---

*EyeSystems*  
60

### S.O.A.P

- You must keep & maintain proper records.
- SOAP at a minimum.
- Subjective data: WHAT THE PATIENT TELLS YOU
- Objective data: RESULTS OF ANY TESTING
- Assessment: DIAGNOSIS OF THE PROBLEM
- Plan: FOR MANAGEMENT OR TREATMENT OF EACH PROBLEM

21

---

---

---

---

---


---

---

---

*EyeSystems*  
62

### Responses



- ✓ Set protocols with your doctor.
- ✓ Know response times. Minutes, hours, days.
- ✓ Have a triage checklist.
- ✓ Never diagnose over the phone.
- ✓ Beware reassuring the patient.
- ✓ Stay calm
- ✓ Be patient

---

---

---

---

---

---

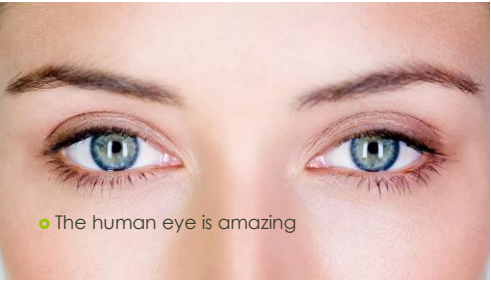
---

---

22

*EyeSystems*  
62

### Conclusion



- The human eye is amazing

---

---

---

---

---

---

---

---

23